

## POSTERS PRESENTATIONS

### FRI-151

#### Treatment and prognosis of hepatic epithelioid hemangioendothelioma based on SEER data analysis from 1973 to 2007

S.S. Kim<sup>1</sup>, J.Y. Cheong<sup>1</sup>, H.J. Cho<sup>1</sup>, S.W. Cho<sup>1</sup>, O.K. Noh<sup>2</sup>. <sup>1</sup>Ajou university school of medicine, Gastroenterology, Suwon; <sup>2</sup>Ajou university school of medicine, Radiation oncology, Suwon  
Email: cocorico99@gmail.com

**Background and Aims:** Malignant hepatic epithelioid hemangioendothelioma (HEH) is a rare malignant tumor of vascular origin with unknown etiology and a variable natural course. This study evaluated the current management and prognosis of HEH status based on SEER data analysis from 1973 to 2007.

**Method:** Using SEER database, a total 79 patients with HEH were analyzed from 1973 to 2014. Patient survival was calculated using Kaplan-Meier survival curves with log rank test.

**Results:** The mean age of patients with HEH was 53.0 years, and the male to female ratio was 1:2.6. About one third (40.8%) of patients were diagnosed at regional metastatic stage followed by local (30.3%) and distant metastatic stage (28.9%). Median tumor size was 3.85cm (IQR, 2.50–7.93cm). Thirty four (43.0%) of patients received no treatment or the treatment information was missing. Of the 45 treated patients, the most common treatment was chemotherapy (48.9%) followed by resection (22.2%). About 22.2% of patients were treated with more than one method. The 1-year and 5-year survival rates were 88% and 88%, respectively in resection or liver transplantation group; 72% and 49%, respectively in other treatment or observation group. Resection or liver transplantation based treatment was only independent predictive factor for survival (hazard ratio 0.17, 95% confidence interval 0.04–0.75, P = 0.020).

**Conclusion:** Resection or liver transplantation is worth considering for treatment of patients with HEH.

### FRI-152

#### The validity of serum midkine, dickkopf-1 and alpha-L-fucosidase as surrogate biomarkers for the diagnosis of hepatocellular carcinoma

N.A. Habachi<sup>1,2</sup>, A. El-Shayeb<sup>2,3</sup>, A. Mansour<sup>2,4</sup>, M. Zaghoul<sup>2,5</sup>. <sup>1</sup>Alexandria University, Faculty of Medicine, Physiology department, Alexandria, Egypt; <sup>2</sup>Alexandria University, Faculty of Medicine, Alexandria clinical research center, Alexandria, Egypt; <sup>3</sup>Alexandria University, Faculty of Medicine, Tropical medicine department, Alexandria, Egypt; <sup>4</sup>Alexandria University, Faculty of Medicine, Clinical pathology, Alexandria, Egypt; <sup>5</sup>Kafrelsheikh University, Faculty of Medicine, Hepatology, Gastroenterology and Infectious diseases, Kafr ElSheikh, Egypt  
Email: mariam\_zaghoul@med.kfs.edu.eg

**Background and Aims:** Hepatocellular carcinoma (HCC) is one of the most common cancers worldwide, particularly in Egypt where hepatitis C (HCV) is highly prevalent. Currently, alpha fetoprotein (AFP) level is the gold standard diagnostic tool for detection and monitoring HCC but with low sensitivity. Thus, the identification of alternative or combined serum markers of HCC is highly needed. Therefore, the aim of this work was to verify the value of serum midkine, dickkopf-1 (DKK-1) and alpha-L-fucosidase (AFU) in detection of HCC development in cirrhotic HCV patients.

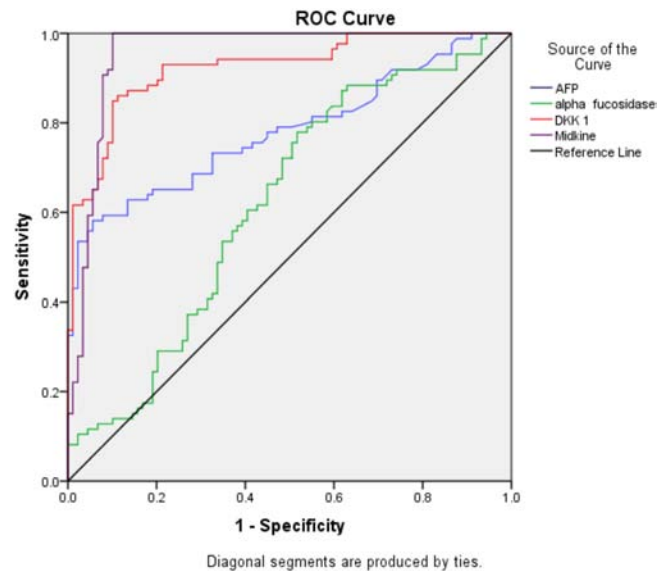
**Method:** Serum midkine, DKK1 and AFU were investigated in 175 patients (89 cirrhotic HCV patients as group I and 86 cirrhotic HCV patients with HCC as group II). Besides, 69 apparently healthy volunteers as controls were enrolled. Serum AFP, midkine, DKK-1 and AFU were measured by ELISA.

**Results:** Serum AFU was significantly higher in group II than in groups I and III (z = 2.75 and 8.99 respectively) (p = 0.006 and 0.00 respectively). Also, serum DKK-1 was significantly higher in group II than in groups I and III (z = 9.66 and 10.55 respectively) (p = 0.00 and 0.00 respectively). Moreover, serum midkine was significantly higher in group II than in groups I and III (z = 10.38 and 10.58 respectively) (p = 0.00 and 0.002 respectively). Both serum DKK-1 and midkine were significantly higher in advanced HCC patients than in those with early HCC (z = 2.64 and 3.05 respectively) (p = 0.008 and 0.002 respectively).

ROC curve analysis showed that the diagnostic potential of serum midkine and DKK-1 to detect HCC occurrence was superior to that of AFP.

	Cut-off value	Specificity	Sensitivity	Positive predictive value	Negative predictive value	Efficacy	AUC
AFP(ng/ml)	40	64%	82%	77%	70.19%	73.14%	0.78
alpha-L-fucosidase (U/l)	0.37	50%	74%	58.33%	65.67%	61.14%	0.62
DKK-1(ng/ml)	2.32	80%	89%	80.2%	88.6%	84%	0.92
Midkine(ng/ml)	5.1	90%	100%	89%	100%	94%	0.95

Using 40ng/ml as a diagnostic cut-off value for AFP, It was diagnostic in 55/86 HCC patients and missed 31 patients (36%). While, serum AFU was positive in 24/31 (77.4%), serum DKK-1 was positive in 28/31 (90%) and serum midkine was positive in 30/31 (96.77%). A logistic regression analysis was performed to ascertain the effects of serum midkine, DKK1 and AFU on the likelihood that cirrhotic HCV patients would have HCC. The logistic regression model was statistically significant  $\chi^2=137.45$  and  $p=0.000$ . Among the three variables tested, only serum midkine and DKK-1 significantly predicted HCC development in cirrhotic HCV patients (p = 0.00 and 0.017 respectively).



**Conclusion:** Serum midkine and DKK-1 are reliable and promising diagnostic as well as prognostic biomarkers for HCC in cirrhotic HCV patients.