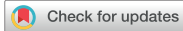

Brief Communication



Imaging Protocol and Criteria for Evaluation of Axillary Lymph Nodes in the NAUTILUS Trial

Jung Min Chang ¹, Hee Jung Shin ², Ji Soo Choi ³, Sung Ui Shin ⁴,
Bo Hwa Choi ⁵, Min Jung Kim ⁶, Jung Hyun Yoon ⁶, Jin Chung ⁷,
Tae Hee Kim ⁸, Boo-Kyung Han ³, Hak Hee Kim ², Woo Kyung Moon ¹

¹Department of Radiology, Seoul National University Hospital, Seoul, Korea

²Department of Radiology and Research Institute of Radiology, Asan Medical Center, Seoul, Korea

³Department of Radiology and Center for Imaging Science, Samsung Medical Center, Seoul, Korea

⁴Department of Radiology, Seoul National University Bundang Hospital, Seoul, Korea

⁵Department of Radiology, National Cancer Center, Goyang, Korea

⁶Department of Radiology, Research Institute of Radiological Science, Severance Hospital, Seoul, Korea

⁷Department of Radiology, Ewha Womans University Mokdong Hospital, Ewha Womans University School of Medicine, Seoul, Korea

⁸Department of Radiology, Ajou University Medical Center, Suwon, Korea

OPEN ACCESS

Received: Oct 7, 2021

Revised: Nov 3, 2021

Accepted: Nov 11, 2021

Correspondence to

Woo Kyung Moon

Department of Radiology, Seoul National University Hospital, 101 Daehak-ro, Jongno-gu, Seoul 03080, Korea.

E-mail: moonwk@snu.ac.kr

© 2021 Korean Breast Cancer Society

This is an Open Access article distributed under the terms of the Creative Commons Attribution Non-Commercial License (<https://creativecommons.org/licenses/by-nc/4.0/>) which permits unrestricted non-commercial use, distribution, and reproduction in any medium, provided the original work is properly cited.

ORCID iDs

Jung Min Chang

<https://orcid.org/0000-0001-5726-9797>

Hee Jung Shin

<https://orcid.org/0000-0002-3398-1074>

Ji Soo Choi

<https://orcid.org/0000-0003-1361-5269>

Sung Ui Shin

<https://orcid.org/0000-0001-6049-8419>

Bo Hwa Choi

<https://orcid.org/0000-0001-7276-1579>

Min Jung Kim

<https://orcid.org/0000-0003-4949-1237>

Jung Hyun Yoon

<https://orcid.org/0000-0002-2100-3513>

Jin Chung

<https://orcid.org/0000-0001-9990-3768>

Tae Hee Kim

<https://orcid.org/0000-0002-0520-2395>



ABSTRACT

Axillary ultrasonography (US) is the most commonly used imaging modality for nodal evaluation in patients with breast cancer. No Axillary Surgical Treatment in Clinically Lymph Node-Negative Patients after Ultrasonography (NAUTILUS) is a prospective, multicenter, randomized controlled trial investigating whether sentinel lymph node biopsy (SLNB) can be safely omitted in patients with clinically and sonographically node-negative T1–2 breast cancer treated with breast-conserving therapy. In this trial, a standardized imaging protocol and criteria were established for the evaluation of axillary lymph nodes. Women lacking palpable lymph nodes underwent axillary US to dismiss suspicious nodal involvement. Patients with a round hypoechoic node with effaced hilum or indistinct margins were excluded. Patients with T1 tumors and a single node with a cortical thickness ≥ 3 mm underwent US-guided biopsy. Finally, patients with negative axillary US findings were included. The NAUTILUS axillary US nodal assessment criteria facilitate the proper selection of candidates who can omit SLNB.

Trial Registration: ClinicalTrials.gov Identifier: [NCT04303715](https://clinicaltrials.gov/ct2/show/study/NCT04303715)

Keywords: Breast Neoplasms; Sentinel Lymph Node Biopsy; Ultrasonography

Sentinel lymph node biopsy (SLNB) is the current standard approach for axillary staging in clinically node-negative patients with early breast cancer. It reduces the risk of morbidity associated with axillary lymph node dissection (ALND) [1]. The landmark Z0011 trial demonstrated no survival benefit associated with axillary dissection, even when one or two positive sentinel lymph nodes (LNs) but no palpable LN were present in patients with T1–2 (< 5 cm) invasive breast cancer treated with breast-conservation surgery and radiotherapy [2]. However, SLNB remains an invasive surgery with a risk of complications and represents a large economic burden on the healthcare system [3]. In the era of mammographic screening,

Boo-Kyung Han 
<https://orcid.org/0000-0003-1896-0571>
Hak Hee Kim 
<https://orcid.org/0000-0002-2956-9212>
Woo Kyung Moon 
<https://orcid.org/0000-0001-8931-3772>

Trial Registration

ClinicalTrials.gov Identifier: [NCT04303715](https://clinicaltrials.gov/ct2/show/study/NCT04303715)

Funding

This research was supported by a grant from the Patient-Centered Clinical Research Coordinating Center (PACEN) funded by the Ministry of Health & Welfare, Republic of Korea (grant number: HI19CO481, HC19CO110).

Conflict of Interest

The authors declare that they have no competing interests.

Author Contributions

Conceptualization: Chang JM, Shin HJ, Moon WK; Data curation: Chang JM, Shin HJ, Choi JS, Shin SU, Choi BH, Kim MJ, Yoon JH, Chung J, Kim TH, Han BK, Kim HH, Moon WK; Formal analysis: Chang JM, Choi BH, Kim MJ, Yoon JH, Chung J, Kim TH, Han BK, Kim HH, Moon WK; Investigation: Chang JM, Shin SU, Moon WK; Methodology: Chang JM, Moon WK; Resources: Chang JM; Supervision: Moon WK; Validation: Chang JM; Writing - original draft: Chang JM, Moon WK; Writing - review & editing: Chang JM, Shin HJ, Choi JS, Shin SU, Choi BH, Kim MJ, Yoon JH, Chung J, Kim TH, Han BK, Kim HH, Moon WK.

the reported sentinel LN positivity rates in highly specialized centers are below 20% [4]. Noninvasive and cost-effective imaging alternatives to SLNB should be considered in early breast cancer patients if the information from SLNB concerning nodal status is of little use as a prognostic indicator, and axillary surgery is not considered to be therapeutic [1].

Axillary ultrasonography (US) is the most commonly used imaging modality for evaluating axillary nodal status in newly diagnosed breast cancer. Axillary US can identify metastatic disease in axillary LNs based on the defined morphologic criteria of normal and suspicious nodes [5]. This provides an opportunity to perform needle biopsies on suspicious nodes, helping to identify candidates for ALND rather than SLNB. There is evidence that disease identified by axillary US suggests a higher axillary nodal burden than that identified by SLNB [6]. Axillary US-positive patients tend to have more positive nodes, larger tumors, higher tumor grades, extranodal extension, and distant metastases [7-9]. After the Z0011 trial, research focused on the ability of axillary US to accurately exclude clinically significant diseases present in the axillae of patients with early breast cancer [7,9,10]. In patients with a negative axillary physical and US examination, the negative predictive value of preoperative axillary US was 89% for the detection of macrometastatic disease (> 2.0 mm tumor deposit) [11], and 95% for detection of low nodal burden disease (≤ 2 macrometastatic nodes) with SLNB [12]. Although the false-negative rate of axillary US remains higher than that of SLNB observed in large, randomized trials (10%), women with false-negative axillary US had recurrence-free survival equivalent to patients with pathologic N0 disease in a retrospective study [11]. Taken together, these data suggest that SLNB represents surgical over-treatment in T1-2 breast cancer patients with a negative axillary US.

No Axillary Surgical Treatment in Clinically Lymph Node-Negative Patients after Ultrasonography (NAUTILUS; NCT04303715) is a prospective, multicenter, phase III randomized controlled trial investigating whether SLNB can be safely omitted in clinically node-negative T1-2 breast cancer patients treated with breast-conserving therapy. The primary endpoint is 5 years of disease-free survival between the non-SLNB (study arm, n = 867) and SLNB (control arm, n = 867) groups. The secondary endpoints are overall survival, distant metastasis rate, regional recurrence rate, local recurrence rate, and self-reported complications. The study design, patient selection, main outcome measures, and statistical analyses were described in the NAUTILUS study protocol. The purpose of this report is to describe the imaging protocol and criteria for the evaluation of axillary LNs for use in the NAUTILUS trial.

The Institutional Review Board approved this retrospective study (IRB No. 2109-130-1257) and waived the requirement for obtaining informed consent from the patients. US equipment with a high-resolution, linear array, electronically focused, high-frequency transducer of at least 12 MHz is recommended with the frequency adjusted as required based on body habitus and imaging findings. Breast radiologists or breast fellows perform axillary US after scanning the entire breast. The patient is placed in a supine oblique position, with the arm abducted and externally rotated with the hand above the head. For a standard axillary US examination, the ipsilateral levels I and II axilla, where the index cancer is located, are scanned. If suspicious LNs are found, additional screening of the internal mammary and infra and supraclavicular areas is performed. Color Doppler images are obtained when deemed necessary by the radiologist. If axillary US reveals normal-appearing LNs only, a single view of a representative axillary LN is recorded. When suspicious LNs are noted, images are acquired in two orthogonal planes (radial, anti-radial, or transverse, longitudinal planes),

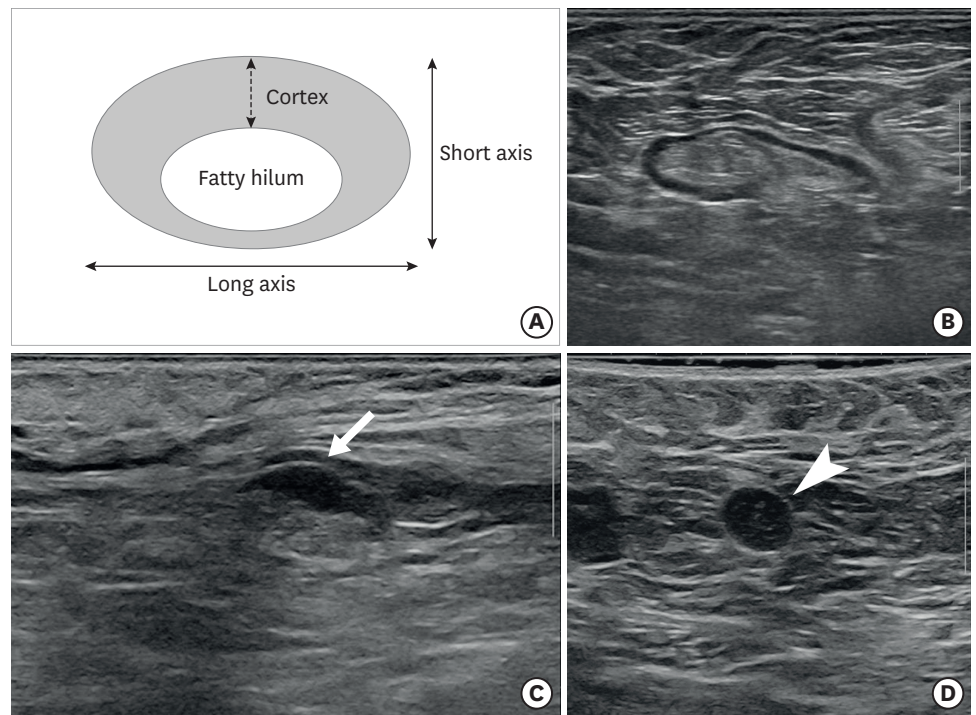


Figure 1. Axillary LN on ultrasonography. (A) Illustration of the procedure for measurement of LN cortical thickness. (B) Representative normal LN. (C) Low suspicion node with focal cortical thickening (arrow). (D) High suspicion node with round shape and complete effacement of fatty hilum (arrowhead) on axillary ultrasonography. The white vertical bar indicates 1 cm (B-D). LN = lymph node.

and the LN maximal cortical thickness is measured in the short-axis direction and recorded [9] (**Figure 1**). In addition, the number of suspicious LNs is documented. US-guided biopsy is recommended when suspicious LNs are noted on axillary US. US-guided fine-needle aspiration (FNA) may be performed when adequate cytology support is available. When not available, a core needle biopsy (CNB) is suggested with a 14-gauge or smaller gauge needle for tissue confirmation of suspicious LNs [5]. The thickened cortex should be the target of the biopsy. Color Doppler is recommended to avoid large vessels during needle biopsy.

Breast radiologists who perform axillary US interpret the axillary US. The NAUTILUS axillary US nodal assessment criteria will be provided to standardize the interpretation across institutions. The criteria are based on a review of the literature and consensus among imaging experts participating in clinical trials. Regarding grading of suspicious levels of axillary LNs according to US findings (**Figure 1**), “normal” is applied to patients without evidence of suspicious LNs, and when all LNs depicted on US are oval shaped with uniformly thin cortex, have smooth margins, and echogenic hilum. “High suspicion” is applied to patients exhibiting LNs with complete or near-complete effacement of the fatty hilum and a round shape, or with indistinct margins. “Low suspicion” is applied to patients exhibiting LNs with either focal or diffuse cortical thickness ≥ 3 mm but no evidence of high suspicion features (**Table 1**). In addition to axillary US findings of morphologic characteristics, the number of suspicious LNs, and the tumor size of index breast cancers (assessed by mammography, breast US, or magnetic resonance imaging [MRI]) should be considered to determine the axillary nodal assessment categories (**Table 2**) and the final eligibility of patients for enrollment. All T1–2 breast cancer patients with no suspicious LN in the axilla

Table 1. Grading of axillary lymph nodes according to US findings

Grade of suspicion	US findings
Normal	Oval shape, smooth margin, and uniformly thin cortex < 3 mm
Low suspicion	Cortical thickness (focal or diffuse) \geq 3 mm without any high suspicion findings
High suspicion*	Complete or near complete effacement of the fatty hilum Round shape Indistinct margin

US = ultrasonography.

*Classified as high suspicion if the lymph node had any of the three findings.

Table 2. Axillary nodal assessment categories in the NAUTILUS trial

Assessment category	Definition	
	Tumor size on imaging*	Nodal status on US
Negative	T1 or T2	LN of normal findings
Indeterminate	T1	1 LN of low suspicion
Positive	T1 or T2	\geq 1 LN of high suspicion
	T1	\geq 2 LN of low suspicion
	T2	\geq 1 LN of low suspicion

NAUTILUS = No Axillary Surgical Treatment in Clinically Lymph Node-Negative Patients after Ultrasonography; T1 = tumor \leq 20 mm in greatest dimension; T2 = tumor > 20 mm but \leq 50 mm in greatest dimension; LN = lymph node; US = ultrasonography.

*Imaging includes mammography and breast ultrasonography (breast magnetic resonance imaging is optional).

on US (negative category) are eligible. For patients with T1 tumors and a single LN with low suspicion of LN (indeterminate category), US-guided FNA or CNB is recommended. Pathologic confirmation of no evidence of metastasis is required for enrollment. Patients are excluded under the following conditions (positive category): T1–2 with one or more LN of high suspicion, T1 with two or more LN of low suspicion, or T2 with one or more LN of low suspicion (**Table 2**). Finally, the enrolled participants are randomized into the non-SLNB and SLNB groups (**Figure 2**).

In this report, we present the imaging protocol and criteria for evaluation of axillary LN to be used in the NAUTILUS trial. As our study aimed to include early breast cancer patients without clinical evidence of LN metastasis, all women with no palpable LN initially undergo axillary US to rule out evident or suspicious nodal involvement. Axillary US is the primary nonsurgical method for evaluating axillary nodes, and axillary US evaluation is routinely performed in the local staging of breast cancer [5]. It is noninvasive, cost-effective, and facilitates image-guided biopsy, if required. However, US is operator-dependent, and standardization of the imaging protocol and diagnostic criteria is important for trials comparing axillary US and SLNB. The NAUTILUS axillary US nodal assessment criteria are constructed based on qualitative and quantitative evaluations that included the morphology and number of suspicious LN and the index tumor size [7,9,10,13].

Our imaging criteria initially graded suspicion of axillary LN into three levels (normal, low suspicion, and high suspicion), according to the LN morphology. It is well known that normal axillary LN should be oval with smooth and well-defined margins, and the cortex should be slightly hypoechoic and uniformly thin, measuring 3 mm or less [14]. LN that satisfy the above-mentioned description have a very high negative predictive value for excluding metastases [7,13]. In contrast, rounded hypoechoic LN with effaced hilum or indistinct margins are highly specific for nodal metastasis [8]. Thus, these features are considered characteristic of high suspicion. If the LN showed focal or diffuse cortical thickening \geq 3 mm but did not show any of the high suspicion features, we defined the LN as low suspicion. Focal cortical bulging, eccentric cortical thickening, or diffuse cortical

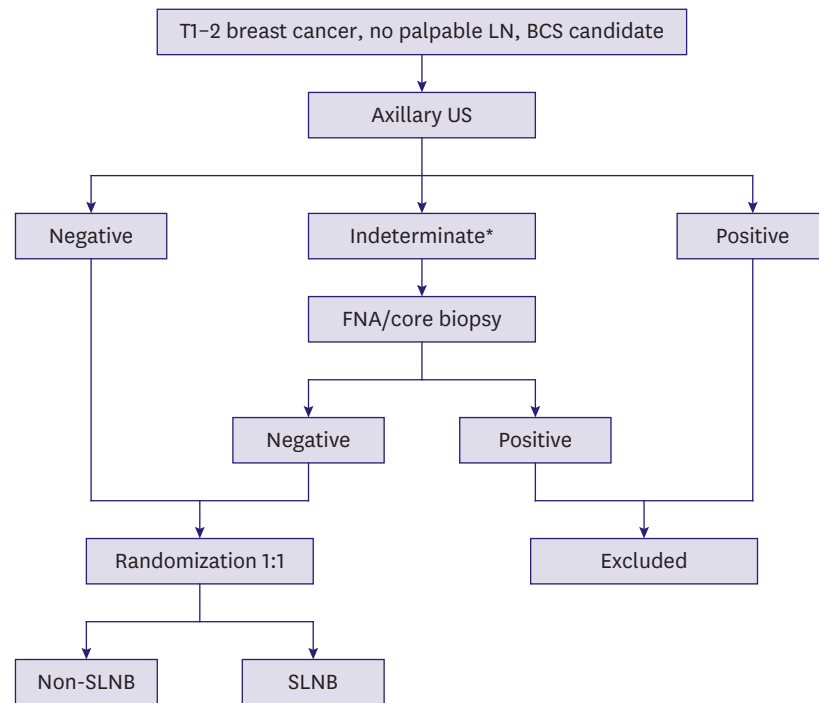


Figure 2. Flowchart illustrating steps in the NAUTILUS trial.

T = tumor; LN = lymph node; BCS = breast-conserving surgery; US = ultrasonography; FNA = fine-needle aspiration; SLNB = sentinel lymph node biopsy; NAUTILUS = No Axillary Surgical Treatment in Clinically Lymph Node-Negative Patients after Ultrasonography.

*Patients with T1 tumor and 1 low suspicious LN on imaging.

thickening can be seen in both reactive and metastatic LNs [8], and a maximum cortical thickness ≥ 3 mm is known to be the most accurate [15]. This cutoff value has been utilized in many previous studies [8,13,15]. Our imaging criteria suggested a quantitative cortical thickness of 3 mm for definition of low suspicion LNs. We believe this criterion can be more objective and may minimize interobserver variability.

In previous studies, not only the morphology of LNs but also the number of suspicious LNs were significantly correlated with nodal burden. The number of abnormal LNs on axillary US was proportional to the number of metastatic nodes in the final pathologic analysis [5,9]. In addition, T2 stage measured on either breast US or MRI was independently associated with a high nodal burden or non-SLN metastasis [9,16]. For these reasons, we combined the numbers of suspicious LNs and index tumor size to define axillary nodal assessment categories and sonographically-negative patients who could be enrolled in the NAUTILUS trial. The patients with no suspicious LNs on US (negative category) are all eligible, whereas patients with high suspicion LNs (positive category) cannot be enrolled regardless of the number of suspicious LNs or index tumor size. Patients with T1 tumors and a low suspicion LN (indeterminate category) can be conditionally enrolled when the LN is the only suspicious node, and the node biopsy result revealed no metastasis. Patients exhibiting two or more suspicious LNs are not eligible for our trial regardless of the index tumor size, because a higher number of suspicious LNs increases the risk of metastasis. Moreover, it is difficult to select the node to be biopsied, and even after the biopsy returns a benign result, the entire nodal status cannot be guaranteed, since other suspicious LNs are not biopsied. The NAUTILUS axillary US nodal assessment criteria will guide the selection of candidates who can omit SLNB.

Eliminating axillary surgery and establishing a minimally invasive procedure is aligned with contemporary research trends (e.g., “de-escalation” or “less is more”) to reduce the burden of treatment for patients. The feasibility of axillary US as an independent staging modality is currently being explored in T1 or T1–2 breast cancer patients treated with breast-conserving therapy. Three large clinical trials comparing axillary US and SLNB are currently underway in Europe: the Sentinel Node vs Observation after Axillary Ultrasound (SOUND) Trial (NCT02167490) [1], the Intergroup-Sentinel-Mamma (INSEMA) trial (NCT02466737) [17], and the Dutch BOOG 2013-08 trial (NCT02271828) [18]. The NAUTILUS study is ongoing with standardized imaging protocols and criteria for the Asian population. This prospective randomized trial will yield crucial information regarding the role of preoperative axillary US in the safe selection of candidates for omission of axillary surgery and the possibility of axillary staging by imaging.

REFERENCES

1. Gentilini O, Veronesi U. Abandoning sentinel lymph node biopsy in early breast cancer? A new trial in progress at the European Institute of Oncology of Milan (SOUND: Sentinel node vs Observation after axillary UltraSouND). *Breast* 2012;21:678-81.
[PUBMED](#) | [CROSSREF](#)
2. Giuliano AE, Hunt KK, Ballman KV, Beitsch PD, Whitworth PW, Blumencranz PW, et al. Axillary dissection vs no axillary dissection in women with invasive breast cancer and sentinel node metastasis: a randomized clinical trial. *JAMA* 2011;305:569-75.
[PUBMED](#) | [CROSSREF](#)
3. Rao R, Euhus D, Mayo HG, Balch C. Axillary node interventions in breast cancer: a systematic review. *JAMA* 2013;310:1385-94.
[PUBMED](#) | [CROSSREF](#)
4. Reimer T, Engel J, Schmidt M, Offersen BV, Smidt ML, Gentilini OD. Is axillary sentinel lymph node biopsy required in patients who undergo primary breast surgery? *Breast Care (Basel)* 2018;13:324-30.
[PUBMED](#) | [CROSSREF](#)
5. Chang JM, Leung JWT, Moy L, Ha SM, Moon WK. Axillary nodal evaluation in breast cancer: state of the art. *Radiology* 2020;295:500-15.
[PUBMED](#) | [CROSSREF](#)
6. Tandon M, Ball W, Kirby R, Soumian S, Narayanan S. A comparative analysis of axillary nodal burden in ultrasound/biopsy positive axilla vs ultrasound negative sentinel lymph node biopsy positive axilla. *Breast Dis* 2019;38:93-6.
[PUBMED](#) | [CROSSREF](#)
7. Neal CH, Daly CP, Nees AV, Helvie MA. Can preoperative axillary US help exclude N2 and N3 metastatic breast cancer? *Radiology* 2010;257:335-41.
[PUBMED](#) | [CROSSREF](#)
8. Ecanow JS, Abe H, Newstead GM, Ecanow DB, Jeske JM. Axillary staging of breast cancer: what the radiologist should know. *Radiographics* 2013;33:1589-612.
[PUBMED](#) | [CROSSREF](#)
9. Abe H, Schacht D, Sennett CA, Newstead GM, Schmidt RA. Utility of preoperative ultrasound for predicting pN2 or higher stage axillary lymph node involvement in patients with newly diagnosed breast cancer. *AJR Am J Roentgenol* 2013;200:696-702.
[PUBMED](#) | [CROSSREF](#)
10. Cho N, Moon WK, Han W, Park IA, Cho J, Noh DY. Preoperative sonographic classification of axillary lymph nodes in patients with breast cancer: node-to-node correlation with surgical histology and sentinel node biopsy results. *AJR Am J Roentgenol* 2009;193:1731-7.
[PUBMED](#) | [CROSSREF](#)
11. Tucker NS, Cyr AE, Ademuyiwa FO, Tabchy A, George K, Sharma PK, et al. Axillary ultrasound accurately excludes clinically significant lymph node disease in patients with early stage breast cancer. *Ann Surg* 2016;264:1098-102.
[PUBMED](#) | [CROSSREF](#)

12. Jozsa F, Ahmed M, Baker R, Douek M. Is sentinel node biopsy necessary in the radiologically negative axilla in breast cancer? *Breast Cancer Res Treat* 2019;177:1-4.
[PUBMED](#) | [CROSSREF](#)
13. Bedi DG, Krishnamurthy R, Krishnamurthy S, Edeiken BS, Le-Petross H, Fornage BD, et al. Cortical morphologic features of axillary lymph nodes as a predictor of metastasis in breast cancer: *in vitro* sonographic study. *AJR Am J Roentgenol* 2008;191:646-52.
[PUBMED](#) | [CROSSREF](#)
14. Mainiero MB, Cinelli CM, Koelliker SL, Graves TA, Chung MA. Axillary ultrasound and fine-needle aspiration in the preoperative evaluation of the breast cancer patient: an algorithm based on tumor size and lymph node appearance. *AJR Am J Roentgenol* 2010;195:1261-7.
[PUBMED](#) | [CROSSREF](#)
15. Choi YJ, Ko EY, Han BK, Shin JH, Kang SS, Hahn SY. High-resolution ultrasonographic features of axillary lymph node metastasis in patients with breast cancer. *Breast* 2009;18:119-22.
[PUBMED](#) | [CROSSREF](#)
16. Kim GR, Choi JS, Han BK, Lee JE, Nam SJ, Ko EY, et al. Preoperative axillary US in early-stage breast cancer: potential to prevent unnecessary axillary lymph node dissection. *Radiology* 2018;288:55-63.
[PUBMED](#) | [CROSSREF](#)
17. Reimer T, Stachs A, Nekljudova V, Loibl S, Hartmann S, Wolter K, et al. Restricted axillary staging in clinically and sonographically node-negative early invasive breast cancer (c/iT1-2) in the context of breast conserving therapy: first results following commencement of the Intergroup-Sentinel-Mamma (INSEMA) trial. *Geburtshilfe Frauenheilkd* 2017;77:149-57.
[PUBMED](#) | [CROSSREF](#)
18. van Roozendaal LM, Vane MLG, van Dalen T, van der Hage JA, Strobbe LJA, Boersma LJ, et al. Clinically node negative breast cancer patients undergoing breast conserving therapy, sentinel lymph node procedure versus follow-up: a Dutch randomized controlled multicentre trial (BOOG 2013-08). *BMC Cancer* 2017;17:459.
[PUBMED](#) | [CROSSREF](#)