

Primary Malignant Fibrous Histiocytoma of the Kidney

Se Joong Kim¹, Byung Cheol Ahn¹, Sung Ryong Kim¹, Young Bu Kim¹, Hee Jae Joo², Kyi Beom Lee²,
and Young Soo Kim¹

Departments of ¹Urology and ²Pathology, Ajou University School of Medicine, Suwon, Korea.

Primary renal malignant fibrous histiocytoma is a rare tumor of the kidney. It is clinically and radiologically indistinguishable from a renal cell carcinoma. Even following radical surgery, the tumor shows a strong predilection for local recurrence and the prognosis is generally poor. We report on a 32-year-old man with malignant fibrous histiocytoma of the kidney who remained free of recurrence for 1 year after radical nephrectomy.

Key Words: Kidney, histiocytoma, sarcoma, nephrectomy

INTRODUCTION

Malignant fibrous histiocytoma (MFH) is the most common soft tissue sarcoma in adulthood. It was first described by O'Brien and Stout in 1964.¹ Typical sites are the extremities (67 - 75%) and the retroperitoneum (6 - 16%).^{2,4} Primary involvement of the kidney is rare, with only 51 cases having been reported in the literature.^{2,4-18} We report an additional case of primary renal MFH and review the literature.

CASE REPORT

A 32-year-old man presented with indigestion, general weakness, 8-kg weight loss over 1 month, and a palpable right flank mass for 2 weeks. He had also experienced occasional nausea and febrile sensation but denied flank pain, gross hematuria or voiding difficulty. Physical exami-

nation revealed a large, fixed, non-tender mass in the right flank. The hemogram showed an anemia (hemoglobin 8.3 g/dL; hematocrit 25.1%) and a raised erythrocyte sedimentation rate (129 mm/hr). Blood chemistry studies indicated increased aspartate aminotransferase (51 U/L), alanine aminotransferase (94 U/L), and alkaline phosphatase (326 U/L). Ultrasonography and computerized tomography of the abdomen revealed a 15 × 16 cm sized, well-demarcated mass with inhomogeneous enhancement and central necrosis in the lower pole of the right kidney (Fig. 1). There were no involvements of the renal vein, inferior vena cava or lymphadenopathy. Chest x-ray and bone scan were normal. On suspicion of a large renal cell carcinoma, right radical nephrectomy was performed.

Gross examination of the specimen revealed a huge, yellowish white, rubbery, 17 × 13 cm sized mass, with multifocal necrosis in the lower pole of the kidney, and without perinephric, renal pelvic or renal vascular invasion (Fig. 2). Histologically, short spindle and epithelioid histiocytic cells, including multinucleated giant cells, were densely arranged in a whorl-like pattern (Fig. 3). Nuclei revealed anaplasia and increased mitoses. Immunohistochemical staining for CD68 was positive, while for desmin, it was focally positive. The staining for S-100 protein, actin, and pancytokeratin was negative. The microscopic and immunohistochemical findings thus indicated a storiform-pleomorphic type of MFH.

After nephrectomy, the levels of erythrocyte sedimentation rate, aspartate aminotransferase, alanine aminotransferase, and alkaline phosphatase were all normalized. The patient's condition has remained satisfactory without any

Received January 14, 2002

Accepted April 8, 2002

Reprint address: requests to Dr. Se Joong Kim, Department of Urology, Ajou University School of Medicine, San 5, Wonchon-Dong, Paldal-Gu, Suwon 442-721, Korea. Tel: 82-31-219-5272, Fax: 82-31-219-5276, E-mail: sejoong@madang.ajou.ac.kr

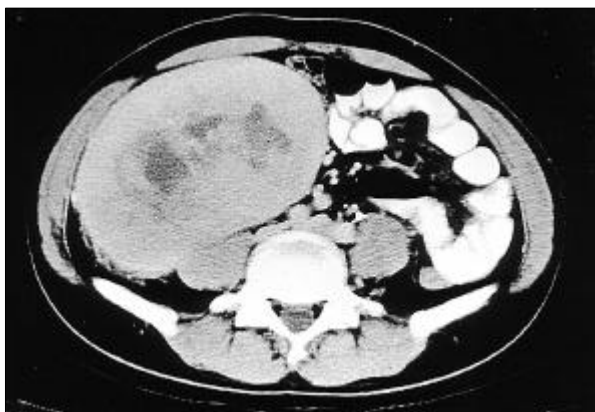


Fig. 1. CT scan revealing a 15×16 cm sized, well-demarcated mass with inhomogeneous enhancement and central necrosis originating in the lower pole of the right kidney.

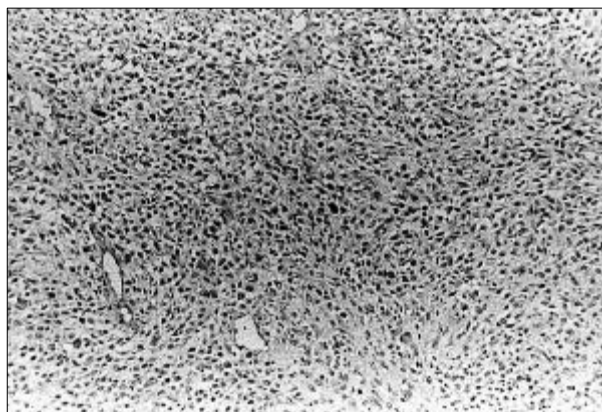


Fig. 3. Microscopic view of spindle and histiocytic cells, including multinucleated giant cells, densely arranged in a whorl-like pattern (H & E, $\times 100$).

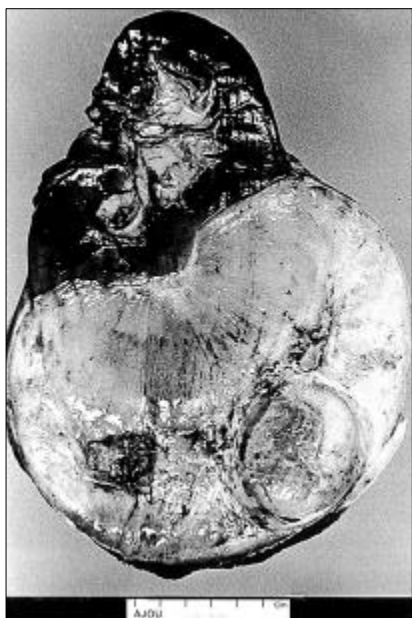

Fig. 2. The sectioned specimen revealed a 17×13 cm sized, yellowish white, rubbery mass with multifocal necrosis in the lower pole of the kidney.

evidence of recurrence for 1 year after nephrectomy.

DISCUSSION

MFH is a primitive mesenchymal tumor with some histiocytic and fibroblastic differentiation.^{1,2} Although occurring predominantly in the extremities, infrequent primary localizations include

the urinary bladder,^{19,20} prostate,^{21,22} spermatic cords^{23,24} and kidneys.^{2,4-18} The latter is a rare MFH site with, to our knowledge, only 51 cases having been reported to date.^{2,4-18}

The histological appearance of MFH is characterized by four subtypes: storiform-pleomorphic, giant-cell, myxoid and inflammatory. The present case also belonged to the storiform-pleomorphic type, which is the most common histologic variant.^{2,4,9}

The clinical symptoms of retroperitoneal MFH are atypical and usually far advanced when symptoms arise. Preoperative differentiation from a renal cell carcinoma is not possible with presently available clinical and imaging techniques, resulting in the definitive diagnosis of MFH being histologic.^{2,4-9,12-18}

In the present case, the increased levels of aspartate aminotransferase, alanine aminotransferase, and alkaline phosphatase were all normalized after nephrectomy, possibly due to paraneoplastic syndrome; however this could not be confirmed. MFH on the neck is sometimes associated with the appearance of hypoglycemia and hyperinsulinemia, which are remitted following tumor removal, since the tumor produces an insulin-like substance.^{3,25} However, abnormal liver function tests, as demonstrated in our case, have not been previously reported in association with MFH.

In a review of all 52 renal MFH cases, including our own,^{2,4-18} patients ranged in age from 32-87

years (mean, 58 years) with our patient being the youngest recorded. Both sexes were equally affected (28 male, 24 female), as were both kidneys (24 right, 26 left, 1 bilateral, 1 not informative). The size of the mass ranged from 5.6-30 cm (mean, 14.9 cm) in longest diameter. The most common presenting symptoms and signs were abdominal or flank pain, palpable mass, generalized weakness and weight loss. Hematuria, present only in 2 cases, was rare,^{8,16} in contrast to being a common symptom and sign of renal cell carcinoma. The diagnostic imaging usually included ultrasonography and computerized tomography. However, preoperative differentiation from a renal cell carcinoma was not possible and treatment was restricted to either simple or radical nephrectomy on the suspicion of renal cell carcinoma, as was the case with our patient.

Radical surgical removal offers the only curative option. Failure of complete resection of the tumor results in a poor prognosis. Even following radical surgery, the tumor often manifests local recurrence with subsequent distant metastases, usually involving the lung and lymph nodes.^{2-10,12-14}

Definitive assessment of the value of adjuvant chemotherapy and/or radiotherapy is impossible due to the small number of reported cases.^{2,21} Takashi et al.⁴ reported a patient free of recurrence for 2 years and 4 months after surgical excision and adjuvant chemotherapy consisting of cyclophosphamide, vincristine, adriamycin and actinomycin D. Papadopoulos and Rudolph² reported a patient free of recurrence for 1 year after tumor nephrectomy, radiotherapy and chemotherapy with doxorubicin and ifosfamide. On the other hand, Muretto et al.¹⁵ reported the recurrence of metastases in multiple sites 17 months after a patient underwent nephrectomy and adjuvant chemotherapy with adriamycin, vincristine, cyclophosphamide and dacarbazine. In general, MFH seems to be only moderately sensitive to chemotherapy and radiotherapy.^{2,8-17,21}

The prognosis of MFH in retroperitoneal tissues is generally very poor with a recurrence rate of more than 50% and a 5-year survival rate of only 14%, most likely due to late diagnosis and difficult surgical accessibility.^{2,4,6-14} Among 52 reported renal MFH patients, 13 (25%) died within 1 year

of surgery.^{2,4-18} However, the true, one year mortality rate is thought to be even higher because several reports noted the discovery of metastasis within several months of surgery but made no mention of later survival or death. Following the report by Froehner et al.⁷ that early detection of local failure and aggressive salvage therapy might offer the best chance for long-term survival in selected cases in spite of the poor prognosis, close, on-going and life-long follow-up is advisable for patients with renal MFH.

REFERENCES

- O'Brien JE, Stout AP. Malignant fibrous xanthomas. *Cancer* 1964;17:1445-56.
- Papadopoulos I, Rudolph P. Primary renal malignant fibrous histiocytoma. *Urol Int* 1999;63:136-8.
- Weiss SW, Enzinger FM. Malignant fibrous histiocytoma. An analysis of 200 cases. *Cancer* 1978;41:2250-66.
- Takashi M, Murase T, Kato K, Koshikawa T, Mitsuya H. Malignant fibrous histiocytoma arising from the renal capsule: report of a case. *Urol Int* 1987;42:227-30.
- Kanno T, Kamoto T, Terai A, Kakehi Y, Terachi T, Ogawa O. A case of malignant fibrous histiocytoma arising from the renal capsule. *Acta Urol Jpn* 2001;47:95-8.
- Virgili G, Di Stasi SM, Storti L, Orlandi A, Vespasiani G. Successful management of retroperitoneal malignant fibrous histiocytoma involving both kidneys. *Scand J Urol Nephrol* 2000;34:208-10.
- Froehner M, Manseck A, Haase M, Hakenberg OW, Wirth MP. Locally recurrent malignant fibrous histiocytoma: a rare and aggressive genitourinary malignancy. *Urol Int* 1999;62:164-70.
- Ptochos A, Karydas G, Iosifidis N, Tyrothoulakis E, Papazafiriou G, Kehagia-Koutoufari T. Primary renal malignant fibrous histiocytoma. A case report and review of the literature. *Urol Int* 1999;63:261-4.
- Lopez JI, Angulo JC, Flores N, Toledo JD. Malignant fibrous histiocytoma of the renal capsule and synchronous transitional cell carcinoma of the bladder. *Pathol Res Pract* 1996;192:468-71.
- Biermann CW, Schnabel R, de Riese W, Schulze H, Senge T. Diagnosis and therapy of a primary kidney malignant fibrous histiocytoma. *Swiss Surg* 1995;1:291-3.
- Villanueva RR, Nguyen-Ho P, Nguyen GK. Malignant fibrous histiocytoma of the kidney diagnosed by needle aspiration biopsy. *Acta Cytol* 1995;39:598-600.
- Garg P, Dass BK, Singh S. Malignant fibrous histiocytoma of renal capsule. *J Indian Med Assoc* 1995;93:430-2.
- Hansen CP, Jensen LM, Holten I. Malignant fibrous

- histiocytoma of the kidney. *Eur Urol* 1989;16:395-7.
14. Oh BR, Kim BJ, Choi GC, Ryu SB, Min BK. A case of malignant fibrous histiocytoma of the kidney. *Korean J Urol* 1989;30:231-4.
 15. Muretto P, Lemma E, Grianti C, Staccioli MP, Fabbretti G, Sbarbati A. Inflammatory malignant fibrous histiocytoma of the kidney: an immunohistochemical and ultrastructural study. *Tumori* 1985;71:147-53.
 16. McClinton S, Steyn J, Miller ID. Renal malignant fibrous histiocytoma. *Br J Urol* 1990;65:109-11.
 17. Raghavaiah NV, Mayer RF, Hagitt R, Soloway MS. Malignant fibrous histiocytoma of the kidney. *J Urol* 1980;123:951-3.
 18. Scriven RR, Thrasher TV, Smith DC, Stewart SC. Primary renal malignant fibrous histiocytoma: a case report and literature review. *J Urol* 1984;131:948-9.
 19. Goodman AJ, Greaney MG. Malignant fibrous histiocytoma of the bladder. *Br J Urol* 1985;57:106-7.
 20. McCormick SR, Dodds PR, Kraus PA, Lowell DM. Nonepithelial neoplasms arising within vesical diverticula. *Urology* 1985;25:405-8.
 21. Zhang G, Chen KK, Manivel C, Fraley EE. Sarcomas of the retroperitoneum and genitourinary tract. *J Urol* 1989;141:1107-10.
 22. Kulmala RV, Seppanen JH, Vaajalahti PJ, Tammela TL. Malignant fibrous histiocytoma of the prostate. Case report. *Scand J Urol Nephrol* 1994;28:429-31.
 23. Glazier DB, Vates TS, Cummings KB, Pickens RL. Malignant fibrous histiocytoma of the spermatic cord. *J Urol* 1996;155:955-7.
 24. Williamson JC, Johnson JD, Lamm DL, Tio F. Malignant fibrous histiocytoma of the spermatic cord. *J Urol* 1980;123:785-8.
 25. Repassy D, Csata S, Sterlik G, Hazslinszky P. Retroperitoneal malignant fibrous histiocytoma. *Int Urol Nephrol* 1999;31:303-11.