

Extensive form of aplasia cutis congenita: a new syndrome?

Moon-Sung Park, Si-Houn Hahn, Chang-Ho Hong, Jung-Sun Kim, Haeng-Soo Kim

Abstract

Aplasia cutis congenita is a heterogeneous group of conditions usually involving the scalp as well as any other part of the body and is associated with a number of other congenital anomalies. We report on a newborn male with almost complete absence of skin and subcutaneous tissue in association with choanal atresia, syndactyly, imperforate anus, pulmonary hypoplasia, and other anomalies. To our knowledge, this condition, not only in the extent of the lesion but the associated anomalies, has not been reported previously.

(*J Med Genet* 1998;35:609-611)

Keywords: aplasia cutis congenita; choanal atresia; syndactyly

Aplasia cutis congenita (ACC) is the congenital absence of skin, which may occur anywhere on the body, most commonly over the cranial vertex. More than 500 cases have been reported since Cordon described the first case in 1767.¹ At present, because the histological appearance varies, diagnosis rests on the presence of eroded, absent, or scarred areas of skin at birth. There appears to be a clear genetic influence in many cases, and it is unlikely that all the lesions would be caused by the same mechanism. Here, a newborn is reported who had almost entire absence of skin, choanal atresia, syndactyly, imperforate anus, pulmonary hypoplasia, and other anomalies, which have not been described before. Several classifications of this heterogeneous disorder have been proposed,²⁻⁵ but this case does not fit any of them.

Case report

The male baby was born at 38 weeks' gestation with a birth weight of 1480 g (<3rd centile), a length of 42 cm (<3rd centile), a head circumference of 33 cm (25th-50th centile), and a chest circumference of 24 cm (<3rd centile). His Apgar scores at one and five minutes were 2 and 1 and he died 15 minutes after birth despite cardiopulmonary resuscitation. He was the third child of a 35 year old woman who had no history of exposure to any drugs, radiation, or infectious diseases during her pregnancy. The parents were non-consanguineous and had no family history of congenital malformations or other illnesses. Raised levels of maternal serum and amniotic fluid alphafetoprotein were observed at 19 weeks' gestation (32 MOM and 35 MOM, normal 0.5 to 2.4 MOM, respectively). However, fetal ultrasonogram showed no definite abnormalities and

chromosome study showed a 46,XY normal male karyotype.

Immediately after birth, almost entire absence of skin and subcutaneous tissue was noticed apart from small areas on the buttocks and right thigh. The relatively large cranium was covered with thin, transparent, membranous tissue and multiple small pieces of skull bones, vessels, and even brain were seen through it. He presented with choanal atresia, micrognathia, a short, broad based tongue, and two prenatal teeth, but no ear lobes, ear openings, eyelids, or nasal alae (figs 1, 2, and 3). Blood vessels, muscle fibres, and ribs were seen in his trunk and abdomen. The umbilical cord contained two umbilical arteries and two umbilical veins. Syndactyly I-II-III-IV-V was present with stubby toes and dysplastic nails on both feet (fig 3).

The fingers had no nails. The ribs, long bones, and vertebrae showed normal contours on radiographs (fig 4). At necropsy (fig 5), the thoracic cavity showed narrowing with hypoplastic lungs, a thin diaphragm, and hepatomegaly. The trachea was narrow, measuring 3 mm in diameter. The right kidney (3.2 g) was hypoplastic and was smaller than the left kidney (7.2 g); both testes were located in the

Department of
Paediatrics, Ajou
University School of
Medicine, 5
Wonchon-dong,
Paldal-gu, Suwon
442-749, Korea
M-S Park
S-H Hahn
C-H Hong

Department of
Pathology, Ajou
University School of
Medicine, Suwon
442-749, Korea
J-S Kim

Department of
Obstetrics and
Gynaecology, Ajou
University School of
Medicine, Suwon
442-749, Korea
H-S Kim

Correspondence to:
Dr Park.

Received 20 July 1997
Revised version accepted for
publication
10 December 1997

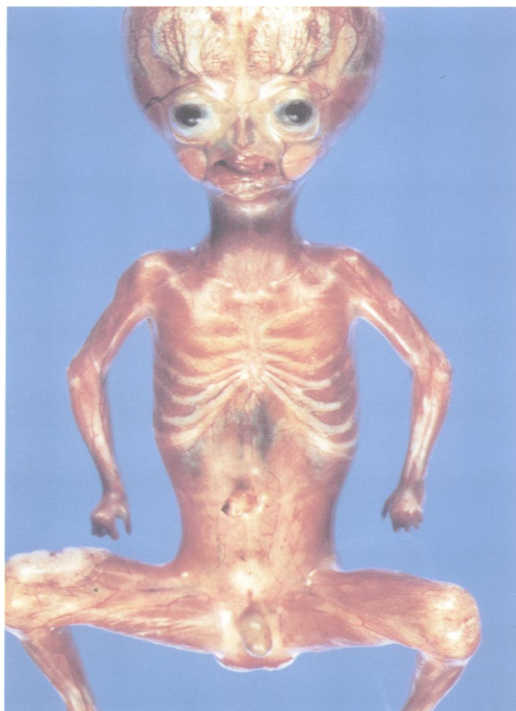


Figure 1 Overview of the patient showed complete absence of skin except on a part of the right thigh and buttock.

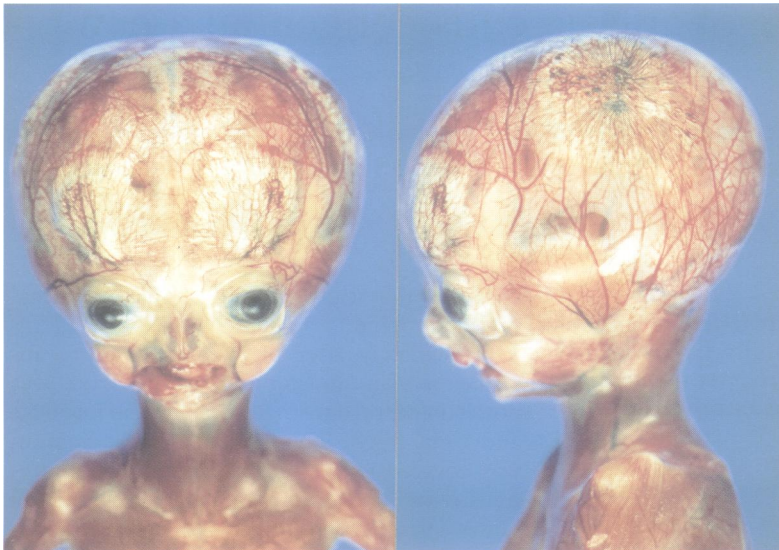


Figure 2 Anterior view of the head (left) showed prenatal teeth and no choanal aperture. The left lateral view of the head (right) showed no ear lobe and no ear canal, and brain could be seen through a thin, transparent membrane which covered small pieces of skull bone.

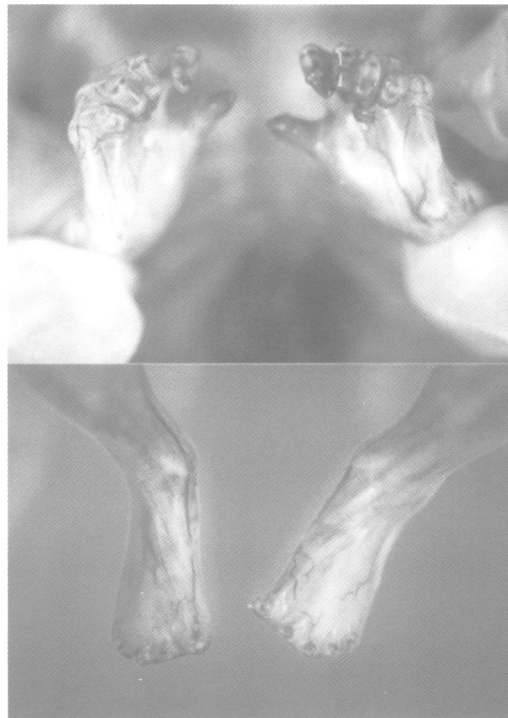


Figure 3 All toes were stubby with dysplastic nails and syndactyly I-II-III-IV-V was present on both feet (below). No fingernails could be seen (above).

pelvic cavity. The other organs, including the heart and brain, showed no definite abnormalities.

On microscopic examination, the external surface of the body showed diffuse complete absence of all layers of the skin; it was covered only by thin fibrous tissue with loss of subcutaneous tissue (fig 6, below). The localised area with skin covering showed flattened, stratified squamous epithelium and dermis, in which there was no evidence of skin appendages (fig 6, above). The diaphragm was composed mainly of connective tissue with a small amount of skeletal muscle fibres and mononuclear cell infiltrates.

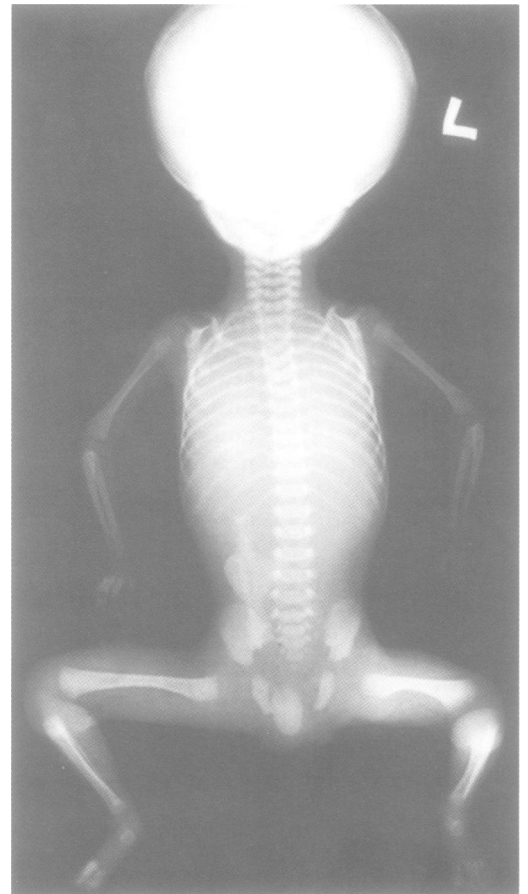


Figure 4 Postmortem radiograph showing normal long bones, ribs, and vertebrae.

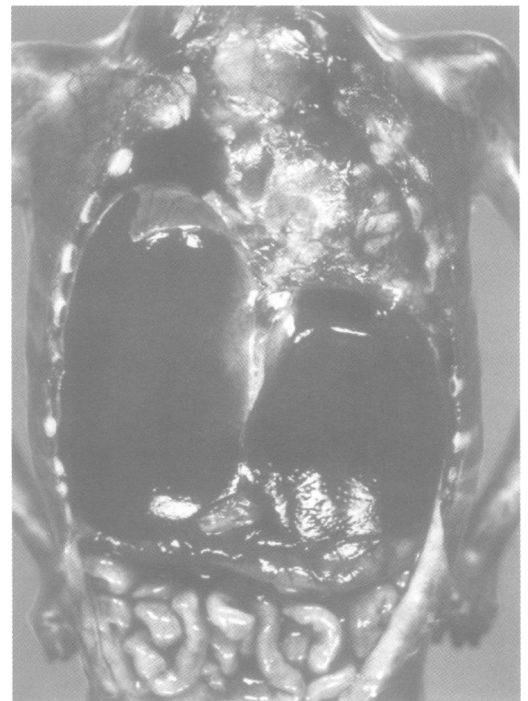

Figure 5 Necropsy showed hypoplastic lungs associated with hepatomegaly and thin diaphragm.

Discussion

In general, ACC is defined as congenital localised absence of skin. Lesions vary in size from pinhead to an extensive symmetrical truncal lesion⁶ and may be single or multiple. In the majority of cases of ACC, the lesion involves

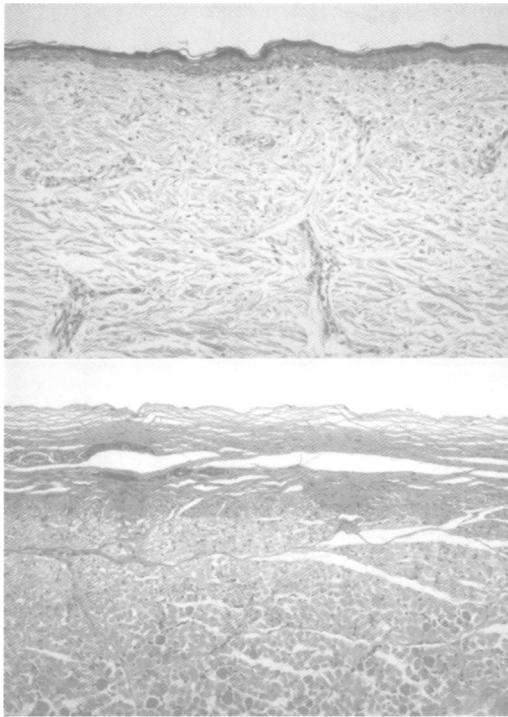


Figure 6 Microscopic finding of tissue from right thigh, where skin remnants remained, showed flattened, stratified squamous epithelium without any skin appendages (above) and the rest of the area covered with thin fibrous tissue without skin (below).

only the epidermis, dermis, and connective tissue; however, in approximately 20% of reported cases there is an underlying bone defect associated with the scalp lesion.⁷ The ACC in this case was so extensive that only tiny areas of skin were left on the buttocks and right thigh and even these showed abnormal skin findings.

This extreme form of aplasia cutis congenita can be distinguished from restrictive dermopathy, Wiedemann-Rautenstrauch syndrome, Hallerman-Streif syndrome, Pallister-Hall syndrome, and Johansen-Blizzard syndrome. Restrictive dermopathy⁸ shows clinical resemblance to this patient, but includes normal long bones. Furthermore, except for small areas on the buttocks and right thigh, the entire skin area was covered with thin, fibrous tissue with no dermis or epidermis. There was no hyperkeratosis which is a consistent finding in restrictive dermopathy.⁸ Wiedemann-Rautenstrauch syndrome⁹ shows similarities to the present patient in the general absence of subcutaneous fat and paradoxical fat accumulation in the flanks, buttocks, and anogenital area, but absence of the dermis and epidermis is not usually seen. Besides, brain pathology did not show sudanophilic leucodystrophy,⁹ which is a consistent neuropathological finding. Johansen-Blizzard syndrome,¹⁰ which shows some of the features of our patient, such as aplasia cutis, imperforate anus, hypoplastic nasal alae, deafness, and pancreatic insufficiency, could be excluded by normal pathology of the pancreas in our patient. Hallerman-Streif syndrome¹¹ and Pallister-Hall syndrome¹² are easily distinguished from the patient on the basis of typical skin, normal eyes, normal clavicles and ribs, normal brain pathology, and normal pituitary gland.

There have been many hypotheses about the pathogenesis of this disease, including the amniogenic theory,¹³ vascular theory,¹⁴ teratogenic action of medications,¹⁵ infectious agents,¹⁶ genetic factors,¹⁸ and so on. However, it is conceivable that one single factor cannot explain the cause of the disease. Several classifications of this heterogeneous disorder have been proposed.³⁻⁵ Recently, Evers *et al*² classified the disease as chromosomal, monogenic, teratological/exogenous, and unknown. Since there was no history of maternal infections or drug intake during pregnancy or family history of similar conditions, monogenic and teratological/exogenous causes for this case can be excluded. The normal karyotype of this patient also excluded the possibilities of trisomy 13 and 18, monosomy 4, and tetrasomy 12p. Type 5 ACC on Frieden's classification⁴ could be considered, but it is unlikely because of the absence of the expected fetus papyraceus or macrosomic evidence of placental abnormalities. Nevertheless, this case had multiple internal organ anomalies which make it difficult to fit into any classification. Therefore, we suggest that this is a new condition of ACC associated with multiple anomalies not described or classified before. For the better classification of ACC, exact pathogenic mechanisms need to be described in the future.

- Cordon M. Extrait d'une lettre au sujet de trois enfants de la même mère nés avec partie des extrémités dénuée de peau. *J Med Chir Pharm* 1767;26:556-7.
- Evers MEJW, Steijlen PM, Hamel BCJ. Aplasia cutis congenita and associated disorder: an update. *Clin Genet* 1995;47:295-301.
- Demmel U. Clinical aspects of congenital skin defects. I. Congenital skin defects on the head of the newborn. II. Congenital skin defects on the trunk and extremities of the newborn. III. Causal and formal genesis of congenital skin defects of the newborn. *Eur J Pediatr* 1975;121:21-50.
- Frieden IJ. Aplasia cutis congenita: a clinical review and proposal for classification. *J Am Acad Dermatol* 1986;14:646-60.
- Sybert VP. Aplasia cutis congenita: a report of 12 new families and review of the literature. *Pediatr Dermatol* 1985;3:1-14.
- Boente MC, Frontini MV, Acosta MI, Saleme C, Barriónuevo S, Asial R. Extensive symmetric truncal aplasia cutis congenita without fetus papyraceus or macroscopic evidence of placental abnormalities. *Pediatr Dermatol* 1995;12:228-30.
- Croce EJ, Purohit RC, Janovski NA. Congenital absence of skin (aplasia cutis congenita). *Arch Surg* 1973;106:732-4.
- Verloes A, Mulliez N, Gonzales M, Laloux F, Hermanns-Lê T. Restrictive dermopathy, a lethal form of arthrogryposis multiplex with skin and bone dysplasia. *Am J Med Genet* 1992;43:539-47.
- Toriello HV. Wiedemann-Rautenstrauch syndrome. *J Med Genet* 1990;27:256-7.
- Hurst JA, Baraitser M. Johanson-Blizzard syndrome. *J Med Genet* 1989;26:45-8.
- Cohen MM Jr. Hallerman-Streif syndrome: a review. *Am J Med Genet* 1991;41:488-99.
- Finnigan DP, Clarren SK, Hass JE. Extending the Pallister-Hall syndrome to include other central nervous system malformations. *Am J Med Genet* 1991;40:395-400.
- Potter EL. *Pathology of the fetus and the infant*. 2nd ed. Chicago: Year Book Medical Publishers, 1961.
- Mannino FL, Jones KL, Benirschke K. Congenital skin defect and fetus papyraceus. *J Pediatr* 1977;91:559-64.
- Mujtaba Q, Burrow GN. Treatment of hypothyroidism in pregnancy with propylthiouracil and methimazole. *Obstet Gynecol* 1975;46:282-6.
- Tomer A, Harel A. Congenital absence of scalp skin and herpes simplex virus. *Isr J Med Sci* 1983;19:950-1.
- Balis FB. Aplasia cutis congenita of neck and shoulder requiring a skin graft: a case report. *Br J Plast Surg* 1983;36:72-4.
- Aknin J, Seguin P, Brunon J, Ouchchane M. Aplasia cutanee du vertex. A propos d'une forme familiale. *Rev Stomatol Chir Maxillofac* 1992;93:267-72.



Extensive form of aplasia cutis congenita: a new syndrome?

M S Park, S H Hahn, C H Hong, et al.

J Med Genet 1998 35: 609-611
doi: 10.1136/jmg.35.7.609

Updated information and services can be found at:
<http://jmg.bmj.com/content/35/7/609>

Email alerting service

These include:

Receive free email alerts when new articles cite this article. Sign up in the box at the top right corner of the online article.

Notes

To request permissions go to:
<http://group.bmj.com/group/rights-licensing/permissions>

To order reprints go to:
<http://journals.bmj.com/cgi/reprintform>

To subscribe to BMJ go to:
<http://group.bmj.com/subscribe/>