

Helicobacter pylori

, * †

. *. † . . .

Early Pathologic Changes of Mouse Gastric Mucosa Infected with *Helicobacter pylori*

**Sang Uk Han, M.D., Hee Jae Joo, M.D.*, Wee Kyo Lee, M.D. †,
Wook Hwan Kim, M.D., Yong Kwan Cho, M.D. and Myung Wook Kim, M.D.**

Departments of Surgery, Pathology and Clinical Pathology †;
Ajou University School of Medicine, Suwon, Korea*

Background/Aims: The aim of the present study was to infect mice with *H. pylori* and then, to evaluate the effects of the infection on the early pathologic changes of gastric mucosa. **Methods:** A mouse- adapted *H. pylori* strain (SS1) was inoculated into 23 C57BL/6 mice. Twelve uninfected mice were also included as controls. The animals were sacrificed 3 days, 4 weeks, 8 weeks and 16 week after being infected with SS1. Gastric tissue were taken for histology and urease test. **Results:** Colonization was detectable in the stomach of all infected animals up to 16 weeks, but not in the control group. The organisms were detected in the mucus layers of the gastric epithelium. In the mice sacrificed 3 days after infection, neutrophil infiltration was identified in submucosal layer and lamina propria. Infiltration of mononuclear cells and mucosal atrophy were observed in the gastric mucosa in the mice sacrificed 4 and 8 weeks after infection respectively. In the mice sacrificed 16 weeks after infection, glandular destruction with severe infiltration of mononuclear cells was developed in the gastric mucosa. **Conclusions:** Acute gastritis occurred from early days after infection with SS1. From 4 weeks after infection, gastric mucosa showed the features of chronic gastritis, progressing to severe atrophy. **(Kor J Gastroenterol 1999;34:1 - 9)**

Key Words: *Helicobacter pylori*, mouse, Gastric mucosa, Gastritis

: 1998 5 30 , : 1999 1 4
: , 442-749,

5 *H. pylori* 10

1920 . 1928

pylori strain
H. pylori

.1
1983

colonization
가 .9

*H. pylori*가

H. pylori
H. pylori

colonization 가

H. pylori

pylori 1)
tion

. 1995 *H.*
coloniza-
, 2)

가 . 3 ,4

H. pylori 가 ,
, 4)

5 *H. pylori*

3)
colonization
, 5) colonization

(Lousanne cri-
teria).10 1997 10 42

가 . 1990 *H. felis*
H. felis
, *H. pylori*

H. pylori
Lousanne criteria
, Sydney

H. felis

가

Strain 1 (SS1)
colonization .11
H. pylori

H. felis
*H. pylori*가

가 . *H. pylori*

H. pylori

H. pylori
3.5 ,

H. pylori

H. pylori

SS1

H. pylori

가

16

C57BL/6

가

0.1 mL

1. SS1

C57BL/6

6

specific pathogen free C57BL/6 Charles River Japan, Inc. (Hae Eun International Co. Ltd)

4.

3 4 , 4 7 , 8 6

1 , 16 6 , SS1

가 ethyl ether

3 12

23 12

2. *H. pylori*

Loussane criteria *H. pylori* strain (SS1)II

modified

Gram's stain

oxidase, catalase urease

6 chocolate

150 μ l , hockey stick

gaspak jar

kit (CampyPak Plus, Becton Dickinson, USA) jar

37 , O2 5%, CO2 10%, N2 85% 3 . 3

brain heart in fusion broth (fetal bovine serum) 5% chocolate

가 1 mL 150 μ l chocolate

3

3.

3

10 μ l 10

10 10

cho-

colate hockey stick

colony

109 CFU/mL

rapid urease test kit (CLO test, Delta West, Australia) urease , 10% 4 μ m H&E

Warthin

1. Urease (Table 1)

23 rapid urease test kit 37 incubator , 2

Table 1. Summary of Positivity of Rapid Urease Test after Inoculation of *H. pylori*

	Infected	Control
3 day	4/4	0/3
4 week	7/7	0/3
8 week	6/6	0/3
16 week	6/6	0/3

9 cryptitis (Fig. 3B). 8
 , 24 가

2. Warthin
 23 War-
 thin , *H.*
pylori crypt S
 , 23
 (Fig. 1). 12

3. (Table 2)
 23 H&E
 , *H. pylori*
 , glandular

glandular
 (Fig.
 2). *H. pylori*
 3
 (Fig. 3A)
 , 4
 (lymphocyte, plasma
 cell)

Fig. 1. Warthin staining of a section of gastric mucosa of C57BL/6 mouse 8 weeks after inoculation with *H. pylori* SS1 (×1000). There are large numbers of *H. pylori* in the mucus overlying the surface and in the top of the gastric pits.

Table 2. Summary of Positivity of Rapid Urease Test after Inoculation of *H. pylori*

Finding	Control	3 days	4 weeks	8 weeks	16 weeks
Neutrophils in lamina propria	0/12	4/4	7/7	6/6	6/6
Neutrophils in epithelial layer	0/12	0/4	4/7	3/6	6/6
Lymphoid cells in lamina propria	0/12	1/4	6/7	6/6	6/6
Lymphoid cells in epithelial layer	0/12	0/4	0/7	1/6	6/6
Submucosal neutrophil aggregate	0/12	1/4	2/7	4/6	6/6
Crypt abscess	0/12	0/4	1/7	1/6	6/6
Mucosal atrophy	0/12	0/4	0/7	2/6	6/6
Intestinal metaplasia	0/12	0/4	0/7	0/6	1/6

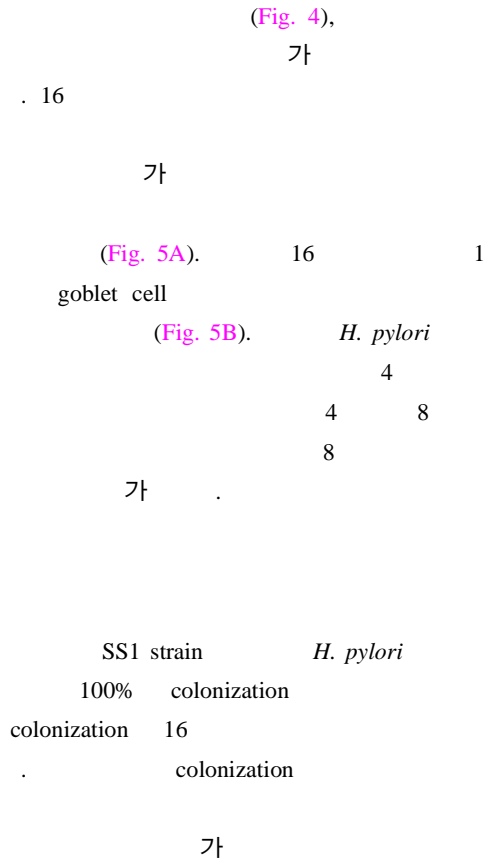


Fig. 2. H&E stained gastric tissue from an uninfected C57BL/6 mouse. No histopathologic changes are observed in the antrum (A, $\times 200$) and body (B, $\times 100$).

Fig. 3. H&E stained gastric tissue from a C57BL/6 mouse infected with *H. pylori* SS1. A few neutrophils have infiltrated the submucosal layer 3 days after inoculation (A, $\times 200$), and a crypt abscess is observed in the epithelium 4 weeks after inoculation (B, $\times 200$).

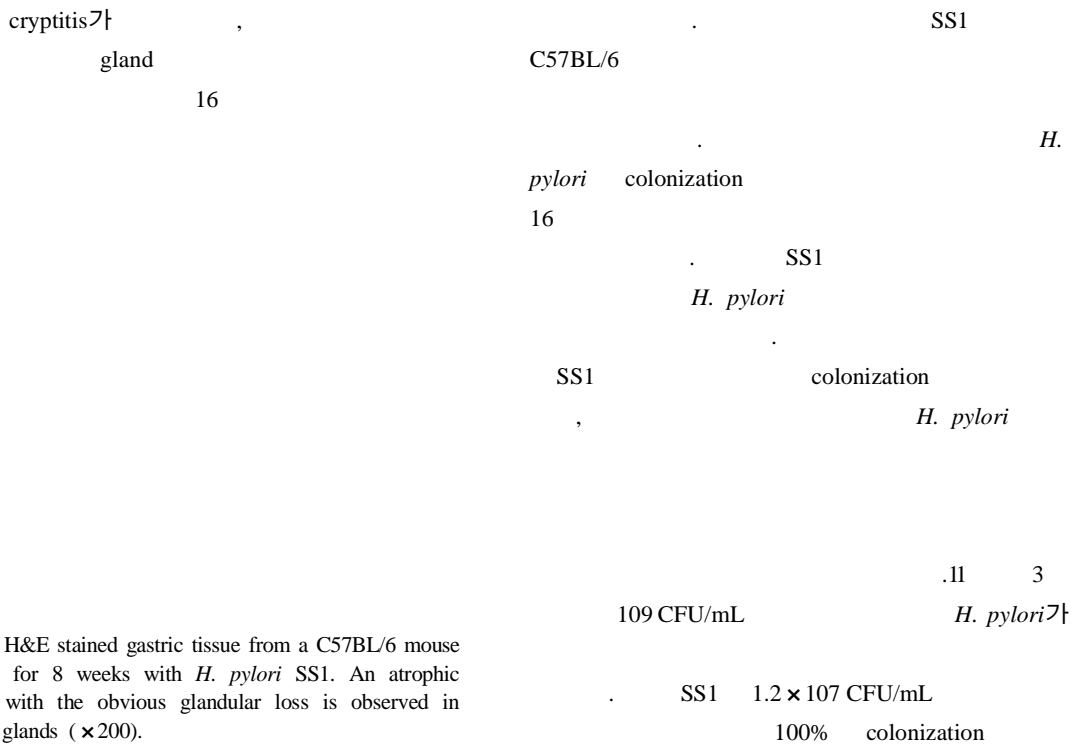


Fig. 4. H&E stained gastric tissue from a C57BL/6 mouse infected for 8 weeks with *H. pylori* SS1. An atrophic change with the obvious glandular loss is observed in pyloric glands ($\times 200$).

Fig. 5. H&E stained gastric tissue from a C57BL/6 mouse infected for 16 weeks with *H. pylori* SS1. An extensive infiltration of inflammatory cells including lymphoid cells with glandular destruction are observed in the lamina propria (A, $\times 400$), and an intestinal metaplasia with goblet cells are observed in the corporeal mucosa (B, $\times 200$).

12 SS1 *H. pylori* (Lausanne criteria) 100% colonization
 C57BL/6 16
 specific pathogen free *H. pylori* SS1
 SS1 가 C57BL/6 *H. pylori*
 II SS1 C57BL/6 *H. pylori*
 가 colonization BALB/c colonization
 가 *H. felis* C57BL/6, BALB/c, *Helicobacter*
 C3H C57BL/6
 가 B colonization
 가 rapid urease test
 SS1 *H. felis*
 가 가 *H. pylori*
 .11 *H. pylori* 가 가
 BALB/c *H. pylori* C57BL/
 BALB/c SS1 6 *H. pylori* 가
 colonization C57BL/6 5% 가
 가 C57BL/6 .11 colo- *H. pylori*
 nization rapid urease test H&E Warthin
 C57BL/6 가 *H.*
 C57BL/6 *pylori* rapid urease
 II BALB/c C57BL/6 test 2
 가 10 가
H. pylori
*H. pylori*가
H. pylori strain (SS1) cagA vacA가
 C57BL/6 106-107 CFU/g tissue *H. pylori*
 colonization , 20 Whitehead 14 가 가
 , 8
 .11

H. pylori

H. pylori 가 updated Sydney System

H. pylori mild, moderate, 16

marked .15 updated Sydney System

H. pylori : *Helicobacter pylori* strain(SS1) 16

H. pylori 11 SS1 C57BL/6 : *H. pylori* strain (SS1) 6 C57BL/6
3.5, 6, 8 6 , SS1 109 CFU/mL . SS1
16 , 8 6 , 16 6 3 4 , 4 7
3 urease H&E Warthin :
4 urease H&E Warthin *H. pylori*
. 8 1/3 urease가 *H. pylori*
. 16 3 , 4
7 *H. pylori* 14 plasma . 8 , crypt ,
.16 3 가
가 SS1 C57BL/6 : SS1 C57BL/6

-
- : *Helicobacter pylori*, , ,
1. Konjetzny GE. Die Entzündungen des Magens. In Henke F, Lubarsch O, eds. Handbuch der Speziellen Pathologischen Anatomie und Histologie IV/2. Berlin: Springer, 1928:768-1116.
 2. Warren JR, Marshall BJ. Unidentified curved bacilli on gastric epithelium in active chronic gastritis. *Lancet* 1983;319:1273-1275.
 3. Krakowka S, Morgan DR, Kraft WG, Leunk RD. Establishment of gastric *Campylobacter pylori* infection in the neonatal gnotobiotic piglet. *Infect Immun* 1987;55:2789-2796.
 4. Radin MJ, Eaton KA, Krakowka S, et al. *Helicobacter pylori* gastric infection in gnotobiotic beagle dogs. *Infect Immun* 1990;58:2606-2612.
 5. Shuto R, Fujioka T, Kubota T, Nasu M. Experimental gastritis induced by *Helicobacter pylori* in Japanese monkeys. *Infect Immun* 1993;61:933-939.
 6. Lee A, Hazell SL, O'Rourke J, Kouprach S. Isolation of a spiral-shaped bacterium from the cat stomach. *Infect Immun* 1988;56:2843-2850.
 7. Lee A, Fox JG, Otto G, Murphy J. A small animal model of human *Helicobacter pylori* active chronic gastritis. *Gastroenterology* 1990;99:1315-1323.
 8. Karita M, Li Q, Cantero D, Okita K. Establishment of a small animal model for human *Helicobacter pylori* infection using germ-free mouse. *Am J Gastroenterol* 1994;2:208-213.
 9. Marchetti M, Arico B, Burrone D, Figura N, Rappuoli R, Ghiara P. Development of a mouse model of *Helicobacter pylori* infection that mimics human disease. *Science* 1995;267:1655-1658.
 10. Michetti M, Wadstrom T, Kraehenbuhl JP, Lee A, Kreiss C, Blum AL. Frontiers in *Helicobacter pylori* research: pathogenesis, host response, vaccine development and new therapeutic approaches. *Eur J Gastroenterol Hepatol* 1996;8:717-722.
 11. Lee A, O'Rourke J, De Ungria MC, Robertson B, Daskalopoulos G, Dixon MF. A standardized mouse model of *Helicobacter pylori* infection: introducing the Sydney strain. *Gastroenterology* 1997;112:1386-1397.
 12. Ferrero RL, Thiberge J, Huerre M, Labigne A. Immune response of specific-pathogen-free mice to chronic *Helicobacter pylori* (strain SS1) infection. *Infect Immun* 1998;66:1349-1355.
 13. Mohammadi M, Redline R, Nedrud J, Czinn S. Role of host in pathogenesis of *Helicobacter*-associated gastritis: *H. felis* infection of inbred and congenic mouse strain. *Infect Immun* 1996;64:238-245.
 14. Whitehead R, Truelove SC, Gear MWL. The histological diagnosis of chronic gastritis in fiberoptic gastroscope biopsy specimens. *J Clin Pathol* 1972;25:1-11.
 15. Dixon MF, Genta RM, Yardley JH, Correa P. Classification and grading of gastritis. The updated Sydney System. International Workshop on the Histopathology of Gastritis, Houston 1994. *Am J Surg Pathol* 1996;29:1161-1181.
 16. Hirayama F, Takagi S, Yokoyama Y, Iwao E, Ikeda Y. Establishment of gastric *Helicobacter pylori* infection in Mongolian gerbils. *J Gastroenterol* 1996;31:24-28.