

## Actinic Granuloma Developed in a Herpes Zoster Scar

Young Jin Kim, M.D., Sung Kwon Kim, M.D., You Chan Kim, M.D.,  
Hee Young Kang, M.D.

*Department of Dermatology, Ajou University School of Medicine, Suwon, Korea*

Wolf's isotopic response describes the occurrence of a new, unrelated disease that appears at the location of a previously healed disease, most commonly herpes zoster. Several cutaneous reactions including granuloma annulare have been known to occur within resolved herpes zoster lesions. We report a case of actinic granuloma which developed on a site previously affected by herpes zoster, and is thought to be an isotopic response. (*Ann Dermatol (Seoul)* 19(1) 35~37, 2007)

*Key Words:* Actinic granuloma, Herpes zoster

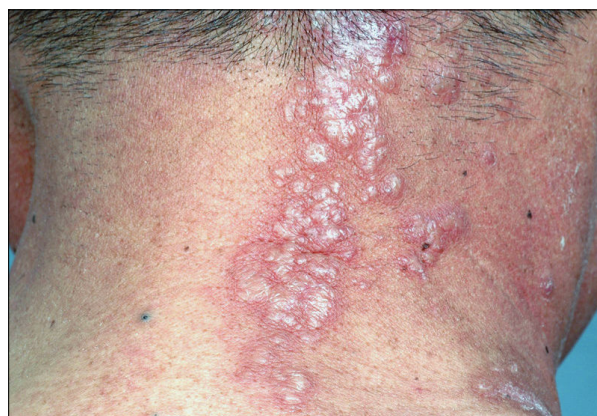### INTRODUCTION

Several cutaneous reactions have been known to be occurring within resolved herpes zoster lesions. These include granulomatous reactions, malignancies, immune disorders, and infections. Among these entities, granuloma annulare is the most commonly reported reaction<sup>1-3</sup>. Herein, we report a case of actinic granuloma which developed on a site previously affected by herpes zoster in a 47-year old man.

### CASE REPORT

A 47-year-old Korean man presented with a 1-month history of a pearly, erythematous, annular eruption on the right side of his posterior neck (Fig. 1). The eruption had a dermatomal distribution (C2-3 areas) exactly corresponding to an area which had been affected by a bout of herpes zoster 2 months before. The patient complained of a persistent burning pain, which was thought to be

postherpetic neuralgia following complete healing of the herpes zoster, but he had no tenderness on the eruption itself. The patient also had a history of malignant melanoma of the paranasal sinus with cervical lymph node metastasis and had undergone endoscopic sinus surgery with bilateral radical neck dissection 18 months before. Laboratory tests including complete blood count, chemical battery and urine analysis were within normal limits. A 3-mm punch biopsy was obtained from a papule near the border of the lesion. The biopsy specimen showed granulomatous inflammation with many multinucleated giant cells engulfing elastotic material

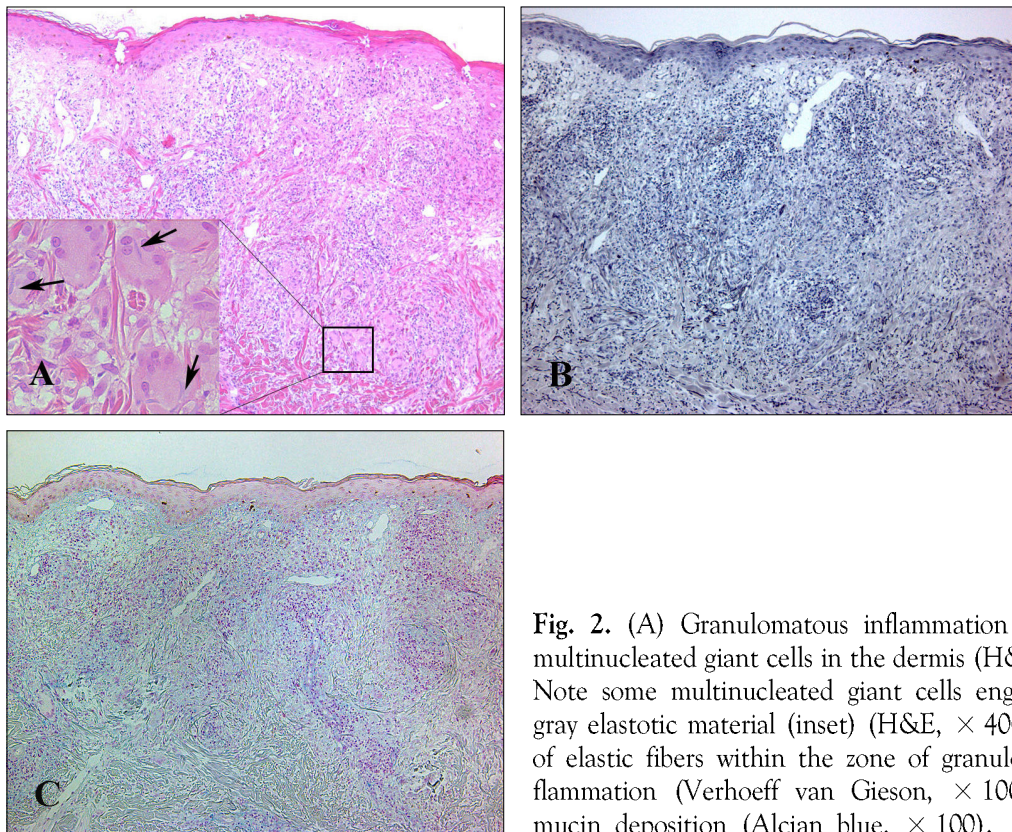


**Fig. 1.** Pearly, erythematous, confluent papules and plaques on the site of a previous herpes zoster. Note the dermatomal distribution (C2-3 areas) of the eruption.

Received February 22, 2006

Accepted for publication February 7, 2007

**Reprint request to:** Hee Young Kang, M.D., Department of Dermatology, Ajou University School of Medicine, 5 Wonchon-dong, Yeongtong-gu, Suwon 443-721, Korea. Tel: 82-31-219-5190, Fax: 82-31-219-5189, E-mail: [hykang@ajou.ac.kr](mailto:hykang@ajou.ac.kr)



**Fig. 2.** (A) Granulomatous inflammation with many multinucleated giant cells in the dermis (H&E,  $\times 100$ ). Note some multinucleated giant cells engulfing blue-gray elastotic material (inset) (H&E,  $\times 400$ ). (B) Loss of elastic fibers within the zone of granulomatous inflammation (Verhoeff van Gieson,  $\times 100$ ). (C) No mucin deposition (Alcian blue,  $\times 100$ ).

in the upper to mid dermis (Fig. 2A). A marked reduction of elastic fibers was noted within the zone of granulomatous inflammation (Fig. 2B). An alcian blue stain showed no mucin deposition on the granuloma (Fig. 2C). The histopathologic findings were consistent with actinic granuloma. The patient was treated by triamcinolone intralesional injection. Six weeks later, the lesions had improved.

## DISCUSSION

In 1995, Wolf et al.<sup>4</sup> first suggested the term "isotopic response" to describe the occurrence of a new skin disorder at the site of another unrelated, and already healed skin disease, most commonly herpes zoster. Several cutaneous granulomatous reactions have been described in areas affected by varicella-zoster virus. Granuloma annulare is the most common disease. Sarcoid and tuberculoid granuloma, granulomatous vasculitis, granulomatous folliculitis, and rarely, Rosai-Dorfman disease and ill-defined granulomatous reactions have also been

reported<sup>1,2,5</sup>. Herein, we report actinic granuloma as a postherpetic isotopic response in herpes zoster.

Actinic granuloma is a rare inflammatory skin disorder which presents in chronically sun-damaged skin as normal-colored to erythematous papules that coalesce to form centrifugally-enlarging annular patterns. The pathogenesis of actinic granuloma remains elusive. It is thought that ultraviolet radiation, heat, or other unknown factors transform the antigenicity of the elastic fibers and induce cellular immune reactions. Immunohistochemical studies showing that  $CD4^+$  cells predominated over  $CD8^+$  cells in the inflammatory infiltrate also support this theory<sup>6,7</sup>. The pathogenesis of isotopic response remains unclear. It was assumed that the viral particles remaining in the tissue were responsible for the occurrence of a second disease. A delayed hypersensitivity response to the virus is probably responsible for granulomatous isotopic responses<sup>5</sup>. However, the role of the viral particle does not seem to be important in all cases because the viral genome has only been detected in early lesions<sup>2,8,9</sup>. Ruocco et al.<sup>1</sup> suggested that an indirect

**Table 1.** Histopathologic Distinction of Actinic Granuloma from Granuloma Annulare

	Granuloma annulare	Actinic granuloma
Epidermis	Normal	Normal or atrophic
Location of Lesion	Superficial dermis	Upper and mid dermis
Necrobiosis	Circumscribed or ill defined	Absent
Mucin	Common	Absent
Lipid	Occasional	Absent
Loss of elastic fibers	Yes	Very marked
Vascular thickening	Common	Absent
Giant cells	Relatively few	Abundant; contain elastic fiber
Asteroid bodies	Absent	Not uncommon
Palisading of histiocytes	Common	Infrequent

Reference 6. McKee PH, Calonje E, Granter SR. Pathology of the skin with clinical correlations. 3rd ed. Philadelphia: Elsevier Mosby, 2005:304.

influence of the nervous system is involved in developing isotopic response. In this hypothesis, the release of specific neuropeptides, triggered by a viral infection, might be the first step with subsequent impairment of immunologic function.

Actinic granuloma should be differentiated from granuloma annulare. It differs substantially from granuloma annulare because of the predominant elastolysis and elastophagocytosis in the absence of necrobiosis, mucin deposition and palisading granuloma<sup>6</sup>. Points of distinction are summarized in Table 1.

In summary, we report a case of actinic granuloma which developed on a site previously affected by herpes zoster, and is thought to be an isotopic response in granuloma.

## REFERENCES

1. Ruocco V, Ruocco E, Ghersetich I, Bianchi B, Lotti T. Isotopic response after herpes virus infection: an update. *J Am Acad Dermatol* 2002;46: 90-94.
2. Requena L, Kutzner H, Escalonilla P, Ortiz S, Schaller J, Rohwedder A. Cutaneous reactions at sites of herpes zoster scars: an expanded spectrum. *Br J Dermatol* 1998;138:161-168.
3. Suh KS, Choi SY, Jeon YS, Sim HJ, Kim ST. A case of granuloma annulare occurring on herpes zoster. *Korean J Dermatol* 2005;43:834-836.
4. Wolf R, Brenner S, Ruocco V, Filioli FG. Isotopic response. *Int J Dermatol* 1995;34:341-348.
5. Schena D, Barba A, Chiericato C. Granulomatous folliculitis as a manifestation of post-herpetic isotopic response. *J Eur Acad Dermatol Venereol* 2001;15:473-475.
6. McKee PH, Calonje E, Granter SR. Pathology of the skin with clinical correlations. 3rd ed. Philadelphia: Elsevier Mosby, 2005:304.
7. Ozkaya-Bayazit E, Buyukbabani N, Baykal C, Ozturk O, Okcu M, Soyer HP. Annular elastolytic giant cell granuloma: sparing of a burn scar and successful treatment with chloroquine. *Br J Dermatol* 1999;140:525-530.
8. Langenberg A, Yen TS, LeBoit PE. Granulomatous vasculitis occurring after cutaneous herpes zoster despite absence of viral genome. *J Am Acad Dermatol* 1991;24:429-433.
9. Serfling U, Penneys NS, Zhu WY, Sisto M, Leonardi C. Varicella zoster virus DNA in granulomatous skin lesions following herpes zoster. A study by the polymerase chain reaction. *J Cutan Pathol* 1993;20:28-33.