

Cutaneous leukocytoclastic vasculitis due to anti-tuberculosis medications, rifampin and pyrazinamide

Joo-Hee Kim,¹ Jun-Il Moon,¹ Jeong Eun Kim,¹ Gil-Soon Choi,¹ Hae-Sim Park,¹ Young-Min Ye,^{1*} Hyunee Yim²

¹Department of Allergy and Rheumatology, Ajou University School of Medicine, Suwon, Korea

²Department of Pathology, Ajou University School of Medicine, Suwon, Korea

This is an Open Access article distributed under the terms of the Creative Commons Attribution Non-Commercial License (<http://creativecommons.org/licenses/by-nc/3.0/>) which permits unrestricted non-commercial use, distribution, and reproduction in any medium, provided the original work is properly cited.

Anti-tuberculosis drugs frequently result in cutaneous adverse reactions, including pruritus, maculopapular exanths, and urticaria. However, anti-tuberculosis drug-associated cutaneous leukocytoclastic vasculitis (CLV) has been rarely reported. We describe a case of CLV induced by rifampin and pyrazinamide. A 38-year-old male had been diagnosed with pulmonary tuberculosis two months ago and then he started standard anti-tuberculosis therapy with isoniazid, rifampin, ethambutol, and pyrazinamide. Purpuric lesions developed in the extremities after 1.5 months of anti-tuberculosis medication; the lesions progressively spread over the entire body. Histopathology of the purpuric skin lesion was consistent with leukocytoclastic vasculitis. The skin lesion improved after cessation of anti-tuberculosis medications and treatment with oral corticosteroids and antihistamines. Anti-tuberculosis drugs were rechallenged one at a time over 3 days. Purpura recurred on the right forearm and forehead after taking 300 mg of rifampin. The skin lesion disappeared after taking oral prednisolone. Finally, 1,500 mg of pyrazinamide was readministered, and then purpuric lesions recurred on both forearms. This report describes a case of leukocytoclastic vasculitis secondary to rifampin and pyrazinamide therapy.

Key Words: Cutaneous leukocytoclastic vasculitis; rifampin; pyrazinamide; pulmonary tuberculosis

INTRODUCTION

Cutaneous leukocytoclastic vasculitis (CLV) is confined to capillaries and post-capillary venules of the superficial plexus.¹ The main clinical lesions of CLV are purpuric papules, although other clinical findings secondary to ischemia, including ulceration, may occur.² Causes of CLV include drugs, infection, connective tissue disease, and malignancy. An estimated 20-30% of all vasculitis cases are attributed to drug administration.³ CLV has rarely been reported in association with tuberculosis or anti-tuberculosis medications.⁴⁻⁶ A case of rifampin-induced Henoch-Schönlein purpura was reported in Korea;⁷ however, the case presented here is, to our knowledge, the first case of CLV following treatment with rifampin and pyrazinamide.

CASE REPORT

A 38-year-old male presented to our hospital emergency room with palpable purpura of the trunk and extremities. He had been diagnosed with pulmonary tuberculosis 2 months earlier. The patient had a history of idiopathic cardiomyopathy and diabetes mellitus; treatment included daily digoxin 0.125

mg, furosemide 40 mg, candesartan cilexetil 8 mg, glimepiride 2 mg, metformin 500 mg, and voglibose 0.6 mg. When the diagnosis of tuberculosis was confirmed by sputum acid fast bacilli (AFB) staining, standard anti-tuberculosis therapy was initiated with isoniazid (Myambutol[®], Yuhan Corp., Suwon, Korea), rifampin (Rifodex[®], Chongkundang, Suwon, Korea), ethambutol (Myambutol[®], Yuhan Corp.), and pyrazinamide (Pyrazinamid[®], Yuhan Corp.). After 1.5 months of anti-tuberculosis therapy, a purpuric, non-blanching rash appeared on the lower and upper extremities. The skin lesions spread progressively over the entire body, and several lesions coalesced, resulting in blisters and ulcers (Fig. 1). The patient had no history of atopy or drug allergy.

Chest radiographs revealed a speculated nodule and multiple satellite nodules in the left upper lung field; this was suggestive

Correspondence to: Young-Min Ye, MD, Department of Allergy and Rheumatology, Ajou University Medical Center, San 5 Wonchon-dong, Yeongtong-gu, Suwon 442-749, Korea.

Tel: +82-31-219-4262; Fax: +82-31-219-4265; E-mail: ye9007@ajou.ac.kr

Received: August 24, 2009; Accepted: November 26, 2009

• There are no financial or other issues that might lead to conflict of interest.

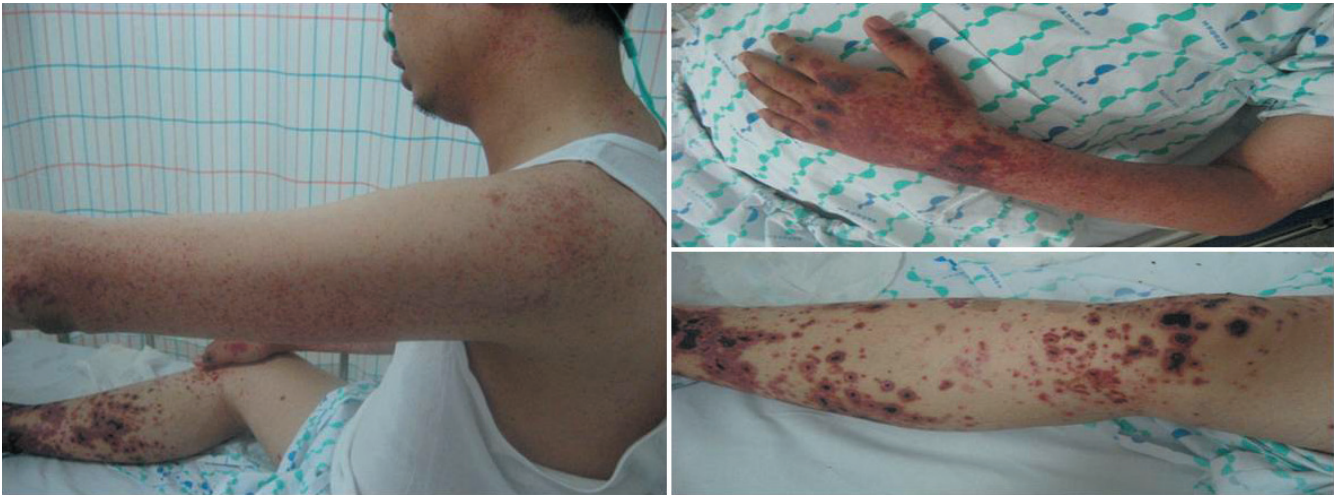

Fig. 1. Palpable purpura and ulcerations developed on the upper and lower extremities of a patient undergoing rifampin and pyrazinamide therapy.

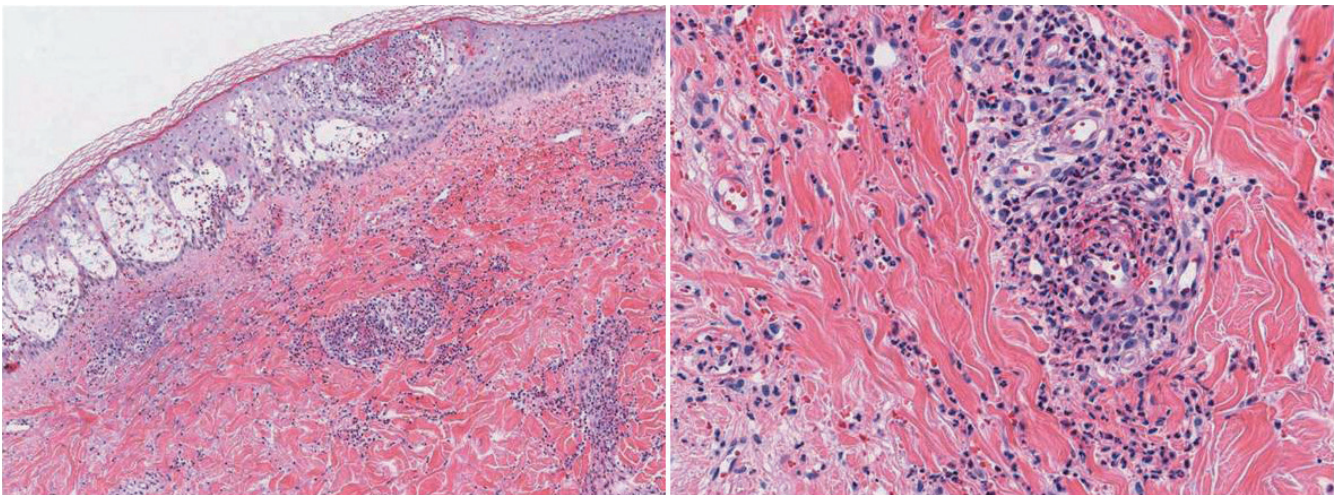


Fig. 2. Biopsy of skin lesions: dermal small vessels show fibrinoid change, perivascular neutrophilic and eosinophilic infiltrate and nuclear debris. This is consistent with the characteristic feature of leukocytoclastic vasculitis.

of pulmonary tuberculosis, with no significant changes from the previous radiographic study. However, the sputum AFB smear had become negative. Blood tests showed the following: leukocytes, $7,500 \times 10^3/\mu\text{L}$ (neutrophils, 76.4%; lymphocytes, 14.0%; monocytes, 7.6%; eosinophils, 0.8%); hematocrit, 37.8%; hemoglobin, 12.4 g/dL; platelet count, $227,000 \times 10^3/\mu\text{L}$; serum creatinine, 1.1 mg/dL; aspartate aminotransferase, 25 U/L; alanine aminotransferase, 18 U/L; HBsAg negative, anti-HBs antibody negative, anti-HCV antibody negative, syphilis serology negative, and anti-HIV negative. Rheumatoid factor, ANA, and ANCA tests were also negative. Prothrombin time and activated partial thromboplastin time were normal. The fibrinogen degradation product and D-dimer were increased to 5.0 $\mu\text{g}/\text{mL}$ (reference range, 0.0-4.0 $\mu\text{g}/\text{mL}$) and 1,225 ng/mL (0-200 ng/mL), respectively. The serum levels of IgG, IgA, IgM, and complement, and the erythrocyte sedimentation rate were within

normal limits. The level of C-reactive protein was slightly elevated at 1.12 mg/dL (0.02-0.80 mg/dL). Urinalysis provided no evidence of proteinuria or hematuria. Skin biopsy of the cutaneous purpuric lesions revealed leukocytoclastic vasculitis (Fig. 2).

The anti-tuberculosis medications were stopped after admission due to a clinical suspicion of a drug-induced adverse cutaneous reaction. Levofloxacin (500 mg) was administered as a second-line anti-tuberculosis medication during hospitalization. The patient was treated with prednisolone (20 mg) for 3 days; the dose was reduced on progressive improvement of the vasculitis lesions. We performed rechallenge with each anti-tuberculosis drug after 10 days, as described in Table 1. No adverse reactions were observed after ethambutol (400 mg) and isoniazid (300 mg) were reintroduced. After rifampin (150 mg) therapy, no specific cutaneous findings were noted, but purpura appeared on the right forearm with increasing the dosage to

Table 1. Time course, dosage and symptom in the rechallenge of anti-tuberculosis medication

Medication	Hospital day (HD)	Dosage	Symptom
Ethambutol (Myambutol [®] , Yuhan)	HD 10	400 mg 2 times a day	None
	HD 11	800 mg once a day	None
Isoniazid (Yuhan-zid [®] , Yuhan)	HD 11	100 mg 3 times a day	None
	HD 12	300 mg once a day	None
Rifampin (Rifodex [®] , Chongkundang)	HD 14	150 mg once a day	None
	HD 15	300 mg 2 times a day	Purpura
Pyrazinamide (Pyrazinamid [®] , Yuhan)	HD 20	500 mg 3 times a day	None
	HD 21	1,500 mg once a day	None
	HD 22	1,500 mg once a day	Purpura

300 mg. The skin lesion resolved after 3 days of prednisolone treatment (20 mg). Pyrazinamide treatment (1,500 mg) was initiated, and new purpuric lesions were seen on both forearms 3 days post-administration. Consequently, he was treated with isoniazid, ethambutol, levofloxacin, and kanamycin without the recurrence of purpura.

DISCUSSION

Cutaneous adverse reactions to anti-tuberculosis drugs have been reported in up to 5% of treated patients.⁸ Common cutaneous reactions include pruritus, skin eruptions, maculopapular exanthems, urticaria, pustules, fixed reactions, and erythema nodosum; these reactions can be controlled with the administration of antihistamines.^{8,9}

Cutaneous leukocytoclastic vasculitis is a rare complication of anti-tuberculosis medications. The combination of vasculitis and tuberculosis was first described in 1967.¹⁰ There are two general types of pulmonary tuberculosis-related vasculitis: leukocytoclastic vasculitis (a manifestation of pulmonary tuberculosis) and anti-tuberculosis medication-associated vasculitis (particularly with rifampin therapy).⁴

Direct vasculitic lesions result from the deposition of bacilli. By contrast, microorganisms are not identified in hypersensitivity vasculitis, which may result from the deposition of immune complexes formed by antibodies against *Mycobacterium tuberculosis* proteins. The existence of such circulating immune complexes has been demonstrated in 56% of patients with active tuberculosis.¹¹ Tuberculids may be a hypersensitivity reaction to *M. tuberculosis* after it spreads hematogenously from a focus of infection elsewhere. Histologically, a tuberculid is composed of granulomatous inflammation, variable necrosis, and variable vasculitis. The lesions respond dramatically to anti-tuberculosis therapy.¹² The possibility of a tuberculosis-associated direct lesion or hypersensitivity vasculitis as the cause of CLV in this patient was unlikely, as the vasculitic lesions developed after 1.5 months of anti-tuberculosis medication. Furthermore, the sputum AFB staining and *M. tuberculosis* cultures were negative at the time the vasculitis developed.

Several studies have described a relationship between rifampin use and vasculitis onset.^{5,6} In contrast to tuberculosis-related vasculitis, the skin lesions of rifampin-induced vasculitis typically improve upon withdrawal of the medication. Previous studies have suggested that anti-rifampin antibodies contribute to the vasculitis pathogenesis.¹³ Although there has been no report of an association between pyrazinamide and vasculitis, the incidence of pyrazinamide-induced hepatotoxicity and other cutaneous adverse reactions is significantly higher than the incidence related to other anti-tuberculosis drugs in Korea and other Western countries.¹⁴⁻¹⁶ The development of urticaria or exanthem within 1 to 2 hours of an initial pyrazinamide dose has been reported,¹⁷ and pyrazinamide-induced erythema multiforme was confirmed by rechallenge in another study.¹⁸ Those studies revealed the causal relationship between the drug and the skin lesions, but no mechanism was documented. Similarly, our patient had a severe cutaneous adverse reaction that improved when the causative drug was withdrawn and recurred after rechallenge. Moreover, there was no cause of the vasculitis except pyrazinamide, and the pathological findings were compatible with leukocytoclastic vasculitis, although the pathogenic mechanism remains unclear.

Risk factors for severe adverse anti-tuberculosis drug reactions include older age, female gender, diabetes mellitus, previous anti-tuberculosis therapy, and a history of hepatitis. Age older than 60 years and a birthplace in Asia are significantly associated with rifampin and pyrazinamide intolerance.¹⁴ Our patient had two risk factors: he was Asian and had diabetes mellitus.

We described a case of rifampin- and pyrazinamide-induced CLV confirmed by histology and drug rechallenge. Although rarely seen, rifampin and pyrazinamide should be considered potential causes of drug-induced CLV.

ACKNOWLEDGMENTS

This research was supported by a grant (09182KFDA847) from Korea Food & Drug Administration in 2009.

REFERENCES

1. Crowson AN, Mihm MC Jr, Magro CM. Cutaneous vasculitis: a review. *J Cutan Pathol* 2003;30:161-73.
2. Justiniano H, Berlinger-Ramos AC, Sanchez JL. Pattern analysis of drug-induced skin diseases. *Am J Dermatopathol* 2008;30:352-69.
3. Khasnis A, Langford CA. Update on vasculitis. *J Allergy Clin Immunol* 2009;123:1226-36.
4. Carvalho M, Dominoni RL, Senchechen D, Fernandes AF, Burigo IP, Doubrawa E. Cutaneous leukocytoclastic vasculitis accompanied by pulmonary tuberculosis. *J Bras Pneumol* 2008;34:745-8.
5. Chan CH, Chong YW, Sun AJ, Hoheisel GB. Cutaneous vasculitis associated with tuberculosis and its treatment. *Tubercle* 1990;71:297-300.
6. Iredale JP, Sankaran R, Wathen CG. Cutaneous vasculitis associated with rifampin therapy. *Chest* 1989;96:215-6.
7. Kim HR, Park BH, Son J-Y, Jung JY, Ahn JR, Jung YS, Lim JE, Jung JW, Moon JA, Byun MK, Kim YS, Kim SK, Chang J, Lee KK, Park MS. A case of Henoch-Shönlein Purpura caused by rifampin. *Tuberc Respir Dis* 2008;65:116-20.
8. Girling DJ, Hitze KL. Adverse reactions to rifampicin. *Bull World Health Organ* 1979;57:45-9.
9. Tan WC, Ong CK, Kang SC, Razak MA. Two years review of cutaneous adverse drug reaction from first line anti-tuberculous drugs. *Med J Malaysia* 2007;62:143-6.
10. Parish WE, Rhodes EL. Bacterial antigens and aggregated gamma globulin in the lesions of nodular vasculitis. *Br J Dermatol* 1967;79:131-47.
11. Johnson NM, McNicol MW, Burton-Kee EJ, Mowbray JF. Circulating immune complexes in tuberculosis. *Thorax* 1981;36:610-7.
12. Barbagallo J, Tager P, Ingleton R, Hirsch RJ, Weinberg JM. Cutaneous tuberculosis: diagnosis and treatment. *Am J Clin Dermatol* 2002;3:319-28.
13. Poole G, Stradling P, Worledge S. Potentially serious side effects of high-dose twice-weekly rifampicin. *Br Med J* 1971;3:343-7.
14. Schaberg T, Rebhan K, Lode H. Risk factors for side-effects of isoniazid, rifampin and pyrazinamide in patients hospitalized for pulmonary tuberculosis. *Eur Respir J* 1996;9:2026-30.
15. Yee D, Valiquette C, Pelletier M, Parisien I, Rocher I, Menzies D. Incidence of serious side effects from first-line antituberculosis drugs among patients treated for active tuberculosis. *Am J Respir Crit Care Med* 2003;167:1472-7.
16. Kim SH, Lee BH, Lee KD, Park JS, Kim YS, Jee YK, Kim SH, Park HS, Min KU. The prevalence of adverse drug reactions to a short course anti-tuberculosis regimen. *Korean J Med* 2007;73:496-502.
17. Ribi C, Hauser C. Adverse reactions to pyrazinamide. *Allergy* 2002;57:964-5.
18. Perdu D, Lavaud F, Prevost A, Deschamps F, Cambie MP, Bongrain E, Barhoum K, Kalis B. Erythema multiforme due to pyrazinamide. *Allergy* 1996;51:340-2.